

# Radiosurgery for patients with unruptured intracranial arteriovenous malformations

## Clinical article

DALE DING, M.D., CHUN-PO YEN, M.D., ZHIYUAN XU, M.D.,  
ROBERT M. STARKE, M.D., M.Sc., AND JASON P. SHEEHAN, M.D., Ph.D.

*Department of Neurological Surgery, University of Virginia Health System, Charlottesville, Virginia*

**Object.** The appropriate management of unruptured intracranial arteriovenous malformations (AVMs) remains controversial. In the present study, the authors evaluate the radiographic and clinical outcomes of radiosurgery for a large cohort of patients with unruptured AVMs.

**Methods.** From a prospective database of 1204 cases of AVMs involving patients treated with radiosurgery at their institution, the authors identified 444 patients without evidence of rupture prior to radiosurgery. The patients' mean age was 36.9 years, and 50% were male. The mean AVM nidus volume was 4.2 cm<sup>3</sup>, 13.5% of the AVMs were in a deep location, and 44.4% were at least Spetzler-Martin Grade III. The median radiosurgical prescription dose was 20 Gy. Univariate and multivariate Cox regression analyses were used to determine risk factors associated with obliteration, postradiosurgery hemorrhage, radiation-induced changes, and postradiosurgery cyst formation. The mean duration of radiological and clinical follow-up was 76 months and 86 months, respectively.

**Results.** The cumulative AVM obliteration rate was 62%, and the postradiosurgery annual hemorrhage rate was 1.6%. Radiation-induced changes were symptomatic in 13.7% and permanent in 2.0% of patients. The statistically significant independent positive predictors of obliteration were no preradiosurgery embolization ( $p < 0.001$ ), increased prescription dose ( $p < 0.001$ ), single draining vein ( $p < 0.001$ ), radiological presence of radiation-induced changes ( $p = 0.004$ ), and lower Spetzler-Martin grade ( $p = 0.016$ ). Increased volume and higher Pittsburgh radiosurgery-based AVM score were predictors of postradiosurgery hemorrhage in the univariate analysis only. Clinical deterioration occurred in 30 patients (6.8%), more commonly in patients with postradiosurgery hemorrhage ( $p = 0.018$ ).

**Conclusions.** Radiosurgery afforded a reasonable chance of obliteration of unruptured AVMs with relatively low rates of clinical and radiological complications.

(<http://thejns.org/doi/abs/10.3171/2013.2.JNS121239>)

**KEY WORDS** • intracranial arteriovenous malformation • radiosurgery • Gamma Knife • vascular malformation • intracranial hemorrhage • stroke • vascular disorders • stereotactic radiosurgery

CEREBRAL AVMs are rare congenital vascular malformations that present equally in both sexes and are typically diagnosed by the 3rd decade of life.<sup>20</sup> The incidence of AVMs as determined by various population-based studies is approximately 1 in 100,000.<sup>3,5,14,15</sup> Historically, the annual hemorrhage risk of AVMs has been considered to be in the range of 2%–4%. The combination of a relatively early age of presentation and the estimated annual risk of hemorrhage leads to the expectation of a high lifetime risk of morbidity from untreated AVMs.<sup>4,11,20</sup> Accordingly, the traditional management of AVMs has been aggressive intervention in the form

of microsurgical resection or radiosurgical obliteration with or without the assistance of pretreatment embolization.<sup>12,13,16,33</sup> While the most common presentation of AVMs remains intracerebral hemorrhage, the number of unruptured AVMs that are diagnosed in patients presenting with seizures, headache, and focal neurological deficits has increased to over half of all identified AVMs, given the wide availability of neuroimaging.<sup>1,29</sup>

Observational studies have suggested that the risk of future morbidity associated with an unruptured AVM might be different from that associated with one that has previously ruptured.<sup>21,30</sup> Therefore, there remains much controversy about the management of unruptured AVMs. Some respected clinicians recommend that intervention for unruptured AVMs may not be superior to conservative management.<sup>31,32,35</sup> In fact, the ARUBA study (A Randomized Trial of Unruptured Brain Arteriovenous

*Abbreviations used in this paper:* ARUBA = A Randomized Trial of Unruptured Brain Arteriovenous Malformations; AVM = arteriovenous malformation; DSA = digital subtraction angiography; HR = hazard ratio; RIC = radiation-induced change.

## Radiosurgery for unruptured intracranial AVMs

Malformations) is underway to look at this issue. In the current study, we present the outcomes of radiosurgical treatment of unruptured AVMs. We determine the post-radiosurgical hemorrhage rate. We also evaluate the rate of success from this approach and the rate of procedure-related morbidity. Finally, we determine factors related to successful obliteration, latency-period hemorrhage, and postradiosurgical complications.

### Methods

#### *Patient Population*

We reviewed a prospective database approved by our institutional review board including a total of 1204 patients with AVMs who were treated with Gamma Knife surgery at the University of Virginia between 1989 and 2009. We identified 522 patients who had unruptured cerebral AVMs at the time of treatment. All patients with less than 2 years of imaging follow-up were excluded, with the exception of patients who demonstrated radiological evidence of total obliteration on either MRI or DSA. We only included patients with a minimum of 2 years' follow-up because it is well known and widely accepted that at least 2 years is typically required for obliteration of AVMs. This left 406 patients who had a minimum of 2 years of imaging and clinical follow-up (mean  $\pm$  SD)  $81 \pm 48$  months or  $6.7 \pm 4.0$  years, median 69 months [IQR 39–116 months] or 5.7 years [IQR 3.3–9.7 years], and range 24–284 months or 2.0–23.7 years). Additionally, there were 38 patients with less than 2 years of imaging follow-up in whom MRI or DSA demonstrated obliteration—on MRI in 14 cases and on DSA in 24, with a mean imaging follow-up of 18 months (SD 5 months) or 1.5 years (SD 0.4 years), median 20 months (IQR 16–22 months) or 1.7 years (IQR 1.3–1.8 years), and range 8–24 months (0.6–2.0 years)—for a total of 444 patients included in our analyses (Fig. 1).

The characteristics of the patients and their AVMs prior to radiosurgery are summarized in Table 1. There were 49 pediatric patients (11.0%), less than 18 years old, and 395 adult patients (89.0%). The most common presenting symptoms were seizure (occurring in 208 patients [46.8%]), headache (123 patients [27.7%]), and focal neurological deficit (53 patients [11.9%]). The Spetzler-Martin grade, which takes into account AVM diameter, presence of deep draining veins, and location in eloquent brain,<sup>28</sup> was I in 81 patients (18.2%), II in 167 (37.6%), III in 163 (36.7%), IV in 30 (6.8%), and V in 3 (0.7%). We also calculated the modified Pittsburgh radiosurgery-based AVM score, which accounts for patient age, deep location, and AVM volume.<sup>36</sup>

#### *Radiosurgery*

The radiosurgical technique for patients with AVMs at our center has been previously described.<sup>33</sup> In brief, under monitored anesthesia for adults and general anesthetic for pediatric patients, a Leksell G-frame was affixed to the patient's head with 4 pins. The patient was then taken to the neurointerventional suite where DSA was performed. An MRI was also obtained. Using a combination of DSA and MRI, the nidus was delineated and treated

with radiosurgery. The mean nidus volume was  $4.2 \pm 3.6$  cm<sup>3</sup> (range 0.1–29.4 cm<sup>3</sup>), the median margin dose (dose to the edge of the AVM nidus) was 20 Gy (IQR 18–23 Gy, range 5–30 Gy), the median maximum dose was 40 Gy (IQR 26–36 Gy, range 10.0–55.6 Gy), the median number of isocenters was 2 (IQR 2–3, range 1–22), and the median isodose was 50% (IQR 50%–50%, range 30%–90%). A total of 64 patients (14.4%) with residual AVMs 3 years after their initial radiosurgery procedures received repeat radiosurgery; 3 patients had 2 repeat treatments and 61 had 1 repeat treatment.

#### *Radiological and Clinical Follow-Up*

Following radiosurgery, patients underwent MRI every 6 months for 2 years and then annually after that. The MRI and DSA studies were performed at a combination of facilities including those at the University of Virginia, outside hospitals, and outpatient centers. All imaging studies were reviewed by an attending neurosurgeon and attending neuroradiologist at the University of Virginia. The overall mean duration of imaging follow-up was  $76 \pm 49$  months or  $6.3 \pm 4.1$  years (median 62 months [IQR 34–111 months] or 5.2 years [IQR 2.8–9.2 years] and range 8–284 months or 0.6–23.7 years). Computed tomography or MRI was performed for neurological deterioration. Hemorrhage was defined by imaging studies, with or without correlation with clinical worsening. Patients were evaluated by DSA to confirm AVM obliteration only after MRI demonstrated absence of a residual lesion. Obliteration was defined by absence of flow voids on MRI or absence of abnormal arteriovenous shunting on DSA. Although DSA is the gold standard for evaluating AVM obliteration, MRI has been shown to have comparable accuracy.<sup>23</sup> Radiation-induced change (RIC) was defined radiologically as T2 hyperintensity surrounding the treated AVM nidus on MRI. Symptomatic RIC was defined as radiological RIC accompanied by clinical signs including headache, seizures, and/or focal neurological deficits. Since the University of Virginia is a tertiary referral center for radiosurgery, clinical follow-up was obtained either directly via the patients' return to our institution's clinics or hospital or, more frequently, indirectly via the patients' local inpatient or outpatient health care facilities. The overall mean duration of clinical follow-up was  $86 \pm 53$  months or  $7.1 \pm 4.4$  years (median 74 months [IQR 38–126 months] or 6.1 years [IQR 3.1–10.5 years], range 7–284 months or 0.5–23.7 years). Figure 2 shows the imaging and clinical follow-up over time for this series of patients.

#### *Analysis*

We performed univariate Cox regressions with IBM SPSS Statistics version 19, using the variables sex, age, preradiosurgery embolization, volume, margin dose, number of isocenters, location of AVM (deep or superficial), venous drainage pattern (deep or superficial), number of draining veins (single or multiple), radiographic evidence of RIC, Pittsburgh radiosurgery-based AVM score, and Spetzler-Martin grade to analyze their effects on obliteration, postradiosurgery hemorrhage, RIC, and postradiosurgery cyst formation. The hazard ratio, 95%

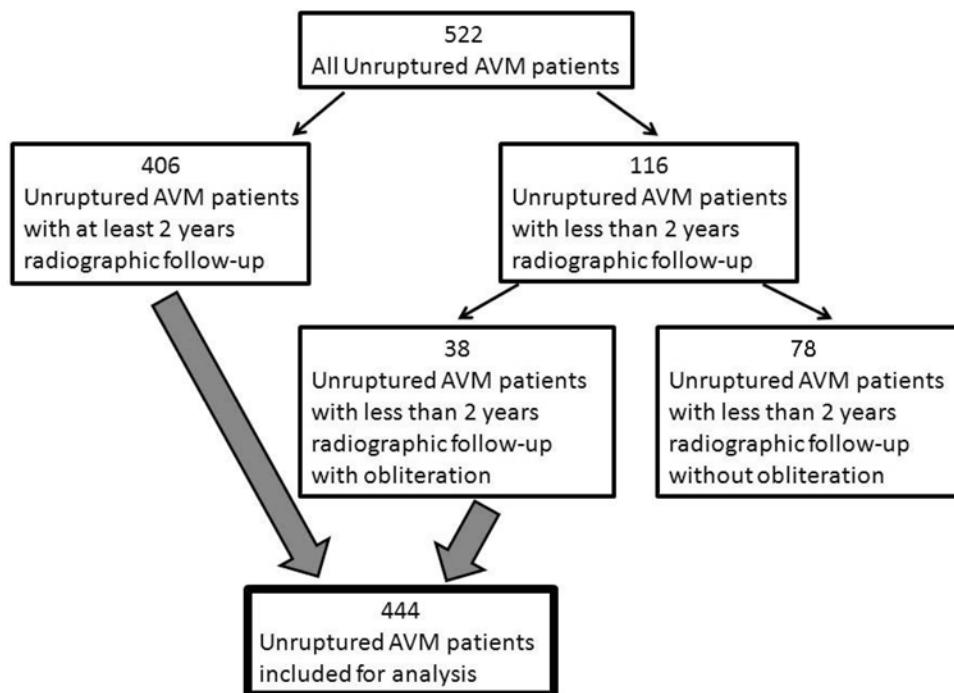


Fig. 1. Composition of patient group.

confidence interval, and p value for each factor were reported. A p value less than 0.05 indicated a statistically significant hazard ratio as did a 95% CI not including 1.0. If more than one variable had a statistically significant hazard ratio, a multivariate Cox regression analysis was employed to determine the independent effects of the univariate significant variables. Kaplan-Meier plot was used to calculate time to obliteration. For hemorrhage risk, the number of risk years was defined as the total time across all patients from radiosurgery to either obliteration or to last imaging follow-up in patients without obliteration.

## Results

### *AVM Obliteration and Factors Predicting Obliteration After Radiosurgery*

Overall, 70 patients (15.8%) had obliteration diagnosed by MRI only and 205 patients (46.2%) had obliteration diagnosed by DSA, for a cumulative obliteration rate of 62%. The postradiosurgery actuarial rate of obliteration was 30% at 3 years, and 53% at 5 years. The actuarial obliteration rate in patients without postradiosurgery hemorrhage, 31% at 3 years and 54% at 5 years, was significantly higher than in patients with postradiosurgery hemorrhage, 24% at 3 years and 36% at 5 years ( $p = 0.018$ ). Figure 3 shows the rate of AVM obliteration over time following radiosurgery. Figure 4 compares the obliteration rate over time for patients with and without postradiosurgery hemorrhage. Table 2 shows the results of univariate and multivariate Cox regression analysis for various patient, AVM, and treatment characteristics and their effects on obliteration rate. Regarding postradiosurgery obliteration, absence of preradiosurgery emboliza-

tion, decreased AVM volume, increased margin dose, superficial venous drainage, single draining vein, radiographic presence of RIC, lower Pittsburgh radiosurgery-based AVM score, and lower Spetzler-Martin grade were found to be statistically significant in the univariate analysis. In the multivariate analysis, no preradiosurgery embolization, increased margin dose, single draining vein, radiological presence of RIC, and lower Spetzler-Martin grade were found to be significant independent positive predictors.

### *Postradiosurgery Hemorrhage Rate and Factors Predicting Hemorrhage*

There were 35 postradiosurgery hemorrhages (29 patients had 1 hemorrhage and 3 had 2 hemorrhages) over 2132 risk years, resulting in an annual hemorrhage risk of 1.6%. Table 3 shows the results of univariate and multivariate Cox regression analysis for multiple factors and their effects on postradiosurgery hemorrhage. The statistically significant positive predictors of hemorrhage in the univariate analysis were increased AVM volume and higher radiosurgery-based AVM score. The multivariate analysis did not demonstrate any independent predictors of postradiosurgery hemorrhage. Of note, no patient with radiologically confirmed obliteration on MRI or DSA had subsequent hemorrhage.

### *Radiation-Induced Changes, Postradiosurgery Cyst Formation, and Radiation-Induced Neoplasia*

Radiation-induced changes were detected on T2-weighted MRI in 216 patients (48.6%) at a mean of  $13 \pm 11$  months after radiosurgery (median 9 months [IQR 6–14 months], range 0–87 months). However, only 61 pa-

# Radiosurgery for unruptured intracranial AVMs

**TABLE 1: Preradiosurgery patient and AVM characteristics in 444 cases**

| Characteristic                          | Value       |
|---|-------------|
| sex                                     |             |
| male                                    | 222 (50.0%) |
| female                                  | 222 (50.0%) |
| age (yrs)                               |             |
| mean                                    | 36.9        |
| median                                  | 35.8        |
| range                                   | 5–82        |
| preradiosurgery embolization            | 122 (27.4%) |
| preradiosurgery microsurgical resection | 20 (4.5%)   |
| location*                               |             |
| superficial                             | 385 (86.7%) |
| deep                                    | 59 (13.3%)  |
| venous drainage pattern                 |             |
| superficial                             | 281 (63.3%) |
| deep                                    | 163 (36.7%) |
| no. of draining veins                   |             |
| single                                  | 208 (46.8%) |
| multiple                                | 236 (53.2%) |
| max diameter (cm)                       |             |
| mean                                    | 2.5         |
| median                                  | 2.4         |
| range                                   | 0.3–6.9     |
| volume (cm <sup>3</sup> )               |             |
| mean                                    | 4.2         |
| median                                  | 3.6         |
| range                                   | 0.1–29.4    |
| max dose (Gy)                           |             |
| mean                                    | 39.5        |
| median                                  | 40.0        |
| range                                   | 10.0–55.6   |
| prescription dose (Gy)                  |             |
| mean                                    | 20.5        |
| median                                  | 20.0        |
| range                                   | 5.0–30.0    |
| isodose                                 |             |
| median                                  | 50%         |
| range                                   | 30–90%      |
| no. of isocenters                       |             |
| mean                                    | 3.1         |
| median                                  | 2           |
| range                                   | 1–22        |
| Spetzler-Martin grade                   |             |
| I                                       | 81 (18.2%)  |
| II                                      | 167 (37.6%) |
| III                                     | 163 (36.7%) |
| IV                                      | 30 (6.8%)   |
| V                                       | 3 (0.7%)    |

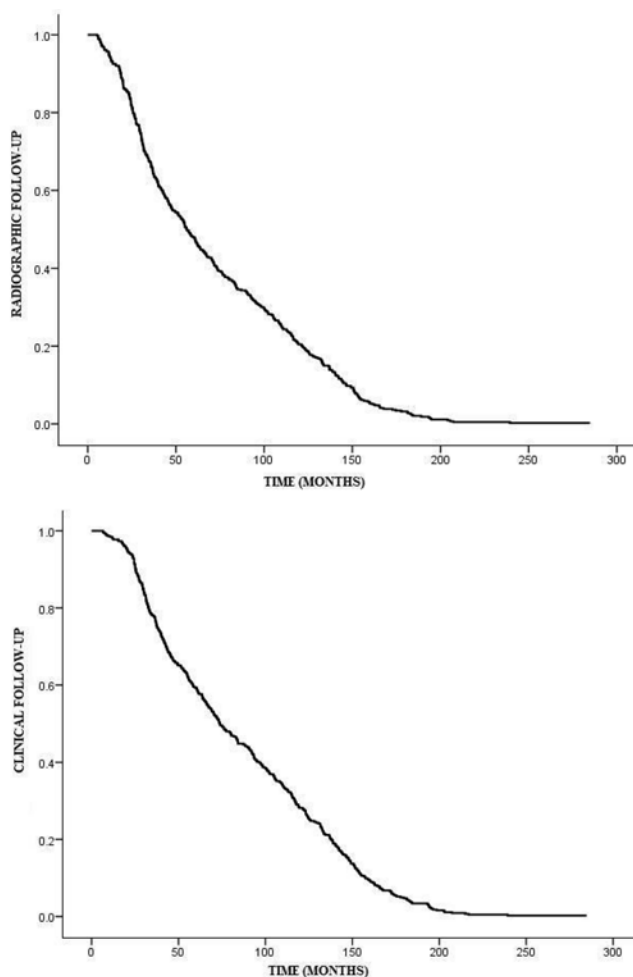
(continued)

**TABLE 1: Preradiosurgery patient and AVM characteristics in 444 cases (continued)**

| Characteristic                          | Value       |
|---|-------------|
| Pittsburgh radiosurgery-based AVM score |             |
| <1.00                                   | 133 (30.0%) |
| 1.01–1.50                               | 212 (47.7%) |
| 1.51–2.00                               | 83 (18.7%)  |
| >2.00                                   | 16 (3.6%)   |
| mean                                    | 1.23        |
| median                                  | 1.19        |
| range                                   | 0.23–4.10   |

\* Deep location includes thalamus, basal ganglia, and brainstem.

tients (13.7%) were symptomatic as a result of RIC. Symptoms included focal neurological deficits in 35 patients (7.9%), headaches in 18 patients (4.1%), and seizures in 13 patients (2.9%). Five patients (1.1%) had more than one of the aforementioned RIC-related symptoms. Radiation-induced changes resulted in permanent symptoms in 9 patients (2.0%). Postradiosurgery cyst formation was seen



**Fig. 2.** Plot showing imaging (upper) and clinical (lower) follow-up for patients with unruptured AVMs.



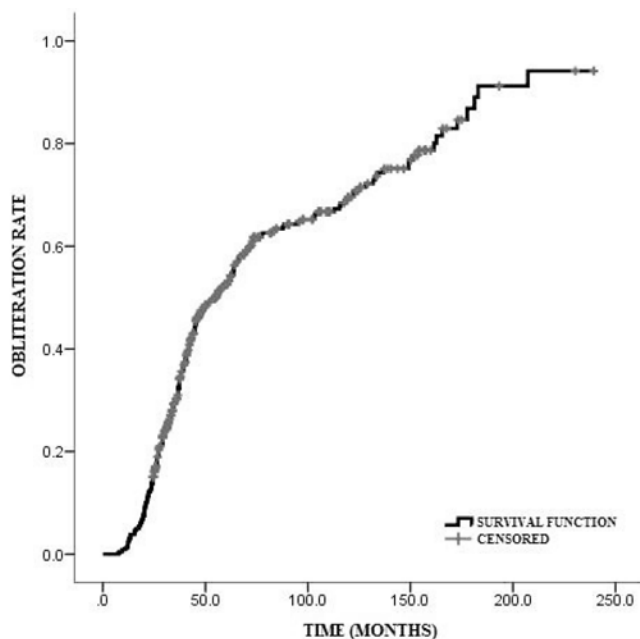


FIG. 3. Plot showing AVM obliteration rate versus time after radiosurgical treatment of unruptured AVMs.

in 10 patients (2.3%) at a mean of  $95 \pm 41$  months or  $7.9 \pm 3.4$  years after treatment (median 80 months [IQR 61–135 months] or 6.6 years [IQR 5.1–11.2 years], range 52–154 months or 4.3–12.9 years after radiosurgery). None of the patients with postradiosurgery cysts required surgical intervention. Tables 4 and 5 show the results of univariate Cox regression analyses for the effects of multiple variables on RIC and postradiosurgery cyst formation, respectively. Multivariate analysis was performed for neither RIC nor postradiosurgery cyst formation because there was no more than one statistically significant variable in either univariate analysis. There were no statistically significant predictors of RIC, although deep location approached statistical significance ( $p = 0.052$ ). The presence of RIC was a statistically significant positive predictor of postradiosurgery cyst formation. In this series, we observed no development of a radiation-induced malignancy following radiosurgery.

#### Clinical Outcomes Following Radiosurgery

At last clinical follow-up after radiosurgery, 32 patients (7.2%) were neurologically improved, 30 patients were neurologically worsened (6.8%), and 382 patients were neurologically unchanged (86.0%) compared with initial presentation. New-onset seizures developed in 4 patients (0.9%) following radiosurgery. Of the group of 208 patients who initially presented with seizures, 105 patients (50.5%) had decreased seizure frequency (including 16 patients [7.7%] who were seizure-free), 10 patients (2.3%) had increased seizure frequency, and 93 patients (44.7%) had unchanged seizure frequency. Of the 32 patients with postradiosurgery hemorrhage, 6 patients (18.8%) experienced clinical deterioration compared with 24 (5.8%) of 411 patients without postradiosurgery hemorrhage who experienced clinical deterioration. By chi-square test, the

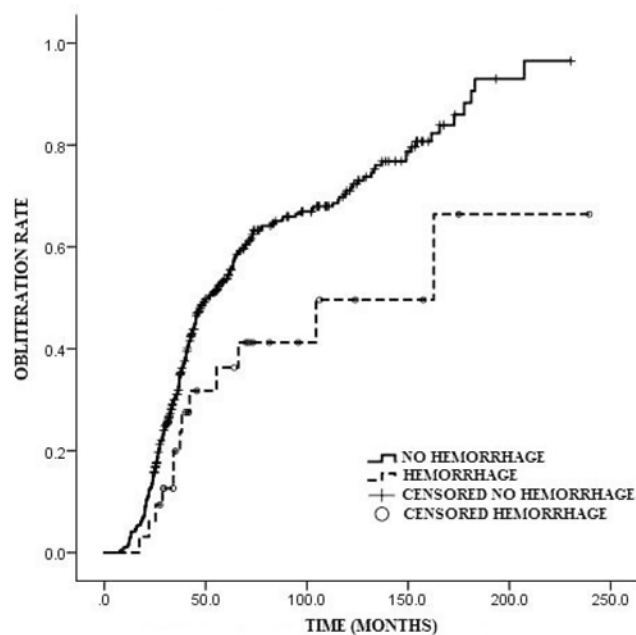


FIG. 4. Plot showing obliteration rate of unruptured AVMs following radiosurgery differentiated by presence of postradiosurgery hemorrhage. Obliteration was significantly more likely in unruptured AVMs without postradiosurgery hemorrhage than in those with postradiosurgery hemorrhage ( $p = 0.018$ ).

incidence of clinical deterioration was significantly higher in patients with postradiosurgery hemorrhage than in patients without postradiosurgery hemorrhage ( $p = 0.018$ ).

## Discussion

The management of unruptured AVMs is controversial. While some experts recommend therapeutic intervention, others do not.<sup>7,31</sup> Several studies suggest that the natural history of unruptured AVMs is more benign than that of ruptured AVMs.<sup>8,21,30</sup> Such controversy has led to initiation of the ARUBA trial, which represents an attempt to evaluate the difference in outcome between no treatment and best available treatment of patients with unruptured AVMs. Although unruptured AVMs seem to have a more favorable natural history, the hemorrhage risk is not negligible and, depending on the lesion size and location, the morbidity associated with hemorrhage may not be inconsequential. In a group of 168 patients with untreated, unruptured AVMs, Brown et al.<sup>4</sup> reported an annual hemorrhage rate of 2.2%.

Radiosurgery offers a minimally invasive method of achieving AVM obliteration, although there has yet to be definitive evidence that the outcomes of treatment, taking into consideration the postradiosurgical complications and hemorrhage during the latency period, are superior to conservative management. From our 20-year institutional experience, radiosurgical treatment of unruptured AVMs seems to provide a favorable risk-benefit profile with a reasonably low postradiosurgery hemorrhage rate (1.6%) and a low risk of permanent neurological deficits associated with radiosurgery (2.0%). Additionally, a high

## Radiosurgery for unruptured intracranial AVMs

**TABLE 2: Factors predicting obliteration after radiosurgery**

| Factor  | Univariate |             |         | Multivariate |             |         |
|---|------------|-------------|---------|--------------|-------------|---------|
|   | HR         | 95% CI      | p Value | HR           | 95% CI      | p Value |
| sex   | 1.156      | 0.912–1.465 | 0.231   | —            | —           | —       |
| increased age                                 | 1.006      | 0.997–1.014 | 0.177   | —            | —           | —       |
| no preradiosurgery embolization               | 2.268      | 1.675–3.067 | <0.001* | 1.901        | 1.364–2.653 | <0.001* |
| decreased volume                              | 1.229      | 1.160–1.302 | <0.001* | 1.056        | 0.989–1.126 | 0.103   |
| increased prescription dose                   | 1.179      | 1.133–1.226 | <0.001* | 1.120        | 1.069–1.173 | <0.001* |
| fewer isocenters                              | 1.055      | 0.985–1.129 | 0.122   | —            | —           | —       |
| superficial location                          | 1.053      | 0.741–1.495 | 0.776   | —            | —           | —       |
| superficial venous drainage                   | 1.279      | 1.081–1.513 | 0.004*  | 1.022        | 0.845–1.236 | 0.823   |
| single draining vein                          | 1.953      | 1.534–2.488 | <0.001* | 1.618        | 1.252–2.088 | <0.001* |
| RICs  | 1.378      | 1.085–1.750 | 0.009*  | 1.429        | 1.122–1.819 | 0.004*  |
| lower Pittsburgh radiosurgery-based AVM score | 2.212      | 1.618–3.030 | <0.001* | 1.202        | 0.814–1.773 | 0.356   |
| lower Spetzler-Martin grade                   | 1.376      | 1.200–1.575 | <0.001* | 1.220        | 1.037–1.435 | 0.016*  |

\* Statistically significant ( $p < 0.05$ ).

percentage of nonhemorrhage–related symptoms resolved after radiosurgery.<sup>33</sup>

The goal of treating AVMs with radiosurgery is to reduce and ultimately, with obliteration, eliminate the future hemorrhage risk. Mechanisms of AVM obliteration following radiosurgery include progressive intimal thickening, thrombosis of irradiated vessels, and eventual occlusion of vascular lumen.<sup>6,26</sup> We have identified factors that correlate with obliteration, postradiosurgery hemorrhage, and postradiosurgery cyst formation. Our study has an inherent selection bias associated with only including patients with at least 2 years of radiographic follow-up. However, most postradiosurgery complications do not occur until 18 months after treatment or later, and the vast majority of AVMs treated with radiosurgery are not obliterated before 2 years after treatment.

Embolization has previously been reported to decrease the radiosurgical obliteration rate of AVMs.<sup>2,22,25</sup>

While it stands to reason that AVMs that require preradiosurgery embolization are, on average, larger than those not requiring embolization, our multivariate analysis demonstrated that embolization was an independent negative predictor of obliteration ( $p < 0.001$ ). The decision to partially embolize an AVM prior to treatment with radiosurgery arises when an AVM is too large—typically greater than 3 cm in maximum diameter or greater than 15 cm<sup>3</sup> in volume—to treat with radiosurgery alone. Therefore, we rely on embolization to reduce the AVM to a targetable size.<sup>27</sup> In these cases, we do not irradiate the embolized portion of the AVM, instead focusing on the remainder of the nidus. Unfortunately, embolization does not guarantee flow cessation, as previously treated arterial feeding vessels have been known to become recanalized.<sup>24</sup> Embolization can make radiosurgical planning more difficult if it fails to target a specific sector of the nidus, potentially transforming a compact nidus into a diffuse one. It has

**TABLE 3: Factors predicting postradiosurgery hemorrhage**

| Factor   | Univariate |              |         | Multivariate |              |         |
|--|------------|--------------|---------|--------------|--------------|---------|
|  | HR         | 95% CI       | p Value | HR           | 95% CI       | p Value |
| sex  | 1.848      | 0.872–3.915  | 0.109   | —            | —            | —       |
| increased age                                  | 1.024      | 0.990–1.059  | 0.170   | —            | —            | —       |
| no preradiosurgery embolization                | 1.340      | 0.619–2.907  | 0.457   | —            | —            | —       |
| increased volume                               | 1.165      | 1.033–1.314  | 0.013*  | 0.991        | 0.808–1.216  | 0.932   |
| decreased prescription dose                    | 1.013      | 0.912–1.125  | 0.807   | —            | —            | —       |
| number of isocenters                           | 1.239      | 0.923–1.663  | 0.154   | —            | —            | —       |
| superficial location                           | 1.195      | 0.406–3.521  | 0.747   | —            | —            | —       |
| deep draining vein(s)                          | 1.218      | 0.776–1.912  | 0.390   | —            | —            | —       |
| multiple draining veins                        | 1.111      | 0.536–2.302  | 0.778   | —            | —            | —       |
| RICs   | 1.355      | 0.640–2.865  | 0.427   | —            | —            | —       |
| higher Pittsburgh radiosurgery-based AVM score | 6.716      | 1.978–22.803 | 0.002*  | 7.225        | 0.910–57.370 | 0.061   |
| higher Spetzler-Martin grade                   | 1.170      | 0.798–1.715  | 0.421   | —            | —            | —       |

\* Statistically significant ( $p < 0.05$ ).

**TABLE 4: Factors predicting postradiosurgery radiation-induced changes**

| Factor  | HR    | 95% CI      | p Value |
|---|-------|-------------|---------|
| sex   | 1.136 | 0.781–1.653 | 0.504   |
| decreased age                                 | 1.001 | 0.989–1.014 | 0.820   |
| no preradiosurgery embolization               | 1.218 | 0.796–1.866 | 0.363   |
| increased volume                              | 1.019 | 0.967–1.075 | 0.480   |
| decreased prescription dose                   | 1.020 | 0.964–1.079 | 0.480   |
| more isocenters                               | 1.003 | 0.926–1.087 | 0.943   |
| deep location                                 | 1.497 | 0.997–2.247 | 0.052   |
| superficial venous drainage                   | 1.087 | 0.842–1.403 | 0.520   |
| multiple draining veins                       | 1.175 | 0.807–1.712 | 0.400   |
| lower Pittsburgh radiosurgery-based AVM score | 1.050 | 0.827–1.332 | 0.690   |
| lower Spetzler-Martin grade                   | 1.235 | 0.994–1.533 | 0.056   |

also been proposed, although not proven, that certain embolization materials, such as Onyx, either scatter or absorb radiation, thereby altering the dose actually delivered to the nidus.<sup>2</sup> Additionally, we must keep in mind that AVM embolization carries its own set of complications, including microcatheter entrapment in cyanoacrylate glue or Onyx, arterial perforation with the microcatheter, AVM hemorrhage due to premature draining vein occlusion, and stroke secondary to reflux of embolic agents into unintended vessels. The combined morbidity and mortality rate from embolization complications is not trivial, exceeding 10% in some studies.<sup>19,34</sup>

In the cases in our study, the AVM nidus was treated with a median margin dose of 20 Gy and the median maximum delivered dose was 40 Gy. Not surprisingly, increased margin dose resulted in increased obliteration ( $p < 0.001$ ). Almost half of the patients showed imaging evidence of postradiosurgery RIC which also independently correlated with obliteration ( $p = 0.004$ ). However, the potential benefit of increasing the radiation dose must be weighed against the increased morbidity that comes with it.<sup>10,17</sup> In our study, we saw a 13.7% rate of symptomatic RIC and a 2.3% rate of posttreatment cyst formation, and we found RIC to be a predictor of cyst formation in univariate analysis ( $p = 0.032$ ). Flickinger et al.<sup>9</sup> demonstrated an increasing rate of permanent radiosurgery-induced deficits as the volume of tissue receiving 12 Gy increased. The same group reported a lower rate of postradiosurgery RIC but comparable rates of symptomatic RIC.<sup>10</sup> In our univariate analysis, the correlation between deep AVM location and RIC approached significance ( $p = 0.052$ ). We otherwise did not identify any significant predictors of RIC.

The presence of a single draining vein was found to be independently correlated with obliteration ( $p < 0.001$ ). An AVM with multiple draining veins will have more complex angioarchitecture and is more likely to have a diffuse nidus than an AVM with a single draining vein. Diffuse AVMs may be difficult to target during treatment planning and may require preradiosurgery embolization and/or staged radiosurgery to be treated successfully. Al-

**TABLE 5: Factors predicting postradiosurgery cyst formation**

| Factor   | HR    | 95% CI       | p Value |
|--|-------|--------------|---------|
| sex  | 2.375 | 0.607–9.346  | 0.214   |
| decreased age                                  | 1.029 | 0.984–1.075  | 0.207   |
| preradiosurgery embolization                   | 2.838 | 0.806–9.988  | 0.104   |
| increased volume                               | 1.030 | 0.887–1.195  | 0.700   |
| increased prescription dose                    | 1.115 | 0.902–1.377  | 0.316   |
| more isocenters                                | 1.043 | 0.994–1.095  | 0.087   |
| superficial location                           | 1.102 | 0.313–3.876  | 0.880   |
| deep venous drainage                           | 1.600 | 0.755–3.390  | 0.220   |
| single draining vein                           | 2.065 | 0.527–8.092  | 0.298   |
| RICs   | 9.659 | 1.213–76.905 | 0.032*  |
| higher Pittsburgh radiosurgery-based AVM score | 1.050 | 0.827–1.332  | 0.690   |
| higher Spetzler-Martin grade                   | 1.615 | 0.793–3.289  | 0.187   |

\* Statistically significant ( $p < 0.05$ ).

though Spetzler-Martin grade was originally developed to predict postoperative morbidity following microsurgical AVM resection, its use as a common way to describe AVMs has become widespread.<sup>28</sup> Lower Spetzler-Martin grade was shown to correlate with obliteration ( $p = 0.016$ ) on multivariate analysis in our study, while the factors that comprise the grading system were not. This suggests that the way in which the Spetzler-Martin grade weighs each AVM characteristic is important for radiosurgical outcomes too.

Finally, we consider whether unruptured AVMs should be treated at all. Generally, the risks associated with stereotactic radiosurgery were temporary; those risks that were permanent were typically not debilitating for the patient. In our series, there was a 6.8% postradiosurgery morbidity rate, one-third of which involved increased seizure frequency. Additionally, those patients who had postradiosurgery hemorrhage were more likely to deteriorate clinically ( $p = 0.018$ ). We report a 1.6% annual hemorrhage risk after radiosurgery for patients with previously unruptured AVMs. This is comparable to or slightly lower than the traditionally quoted annual hemorrhage risk of 2%–4%.<sup>4,11,20</sup> However, studies that have stratified AVMs into risk groups based on various AVM characteristics have shown that those AVMs with low risk factors—such as superficial location, compact nidus, superficial venous drainage, fewer draining veins, and no history of hemorrhage—have annual hemorrhage rates of approximately 1%.<sup>21,30</sup> A randomized trial of unruptured brain AVMs (ARUBA), funded by the National Institute of Neurological Disorders, is currently underway to compare interventional outcomes with natural history.<sup>18</sup> We acknowledge that information about the response of symptoms such as headaches and focal neurological deficits following radiosurgery for unruptured AVMs would be useful to patients and physicians. Unfortunately, we do not have readily available, reliable, and objective assessments of headache response in patients. Moreover, the heterogeneity of neurological deficits as well as the small resulting subgroups for focal neurological deficits would

# Radiosurgery for unruptured intracranial AVMs

preclude any meaningful statistical analysis of symptomatic response in this single-institution series of patients. We hope that such data will be forthcoming in prospective trials like the ARUBA study.

Based upon our experience, we recommend treating patients with unruptured AVMs if they are younger and therefore have more at-risk years for hemorrhage, have a larger-volume AVM, and a higher radiosurgery-based AVM grade. Although the risks from radiosurgery are not inconsequential, the long-term hemorrhage risk of an AVM, even if unruptured at the time of presentation, and the morbidity and mortality associated with an AVM hemorrhage make radiosurgery a reasonable treatment option for some patients with unruptured AVMs.

## Conclusions

Radiosurgery offers a reasonable benefit-to-risk profile for patients with unruptured AVMs. Until the AVMs were obliterated, the cohort of patients with unruptured AVMs demonstrated an annual hemorrhage rate comparable to traditionally quoted figures.

## Disclosure

The authors report no conflict of interest concerning the materials or methods used in the study or the findings specified in this paper.

Author contributions to the study and manuscript preparation include the following. Conception and design: Sheehan, Ding, Yen. Acquisition of data: Sheehan, Yen. Analysis and interpretation of data: Sheehan, Ding, Yen, Xu. Drafting the article: Ding, Yen. Critically revising the article: all authors. Reviewed submitted version of manuscript: all authors. Approved the final version of the manuscript on behalf of all authors: Sheehan. Statistical analysis: Yen, Xu.

## Acknowledgments

The authors acknowledge the contribution of other physicians who participated in the care and treatment of the patients included in this series. At their center, these physicians include but are not limited to Drs. Kassell, Steiner, Prasad, Jensen, Snell, Berk, Lerner, Matsumoto, Lipper, Raghavan, Wintermark, Read, Rich, Evans, Dion, and Quigg. The authors also thank the referring physicians who helped to provide follow-up information on many of the patients from remote locations.

## References

1. Al-Shahi R, Bhattacharya JJ, Currie DG, Papanastassiou V, Ritchie V, Roberts RC, et al: Prospective, population-based detection of intracranial vascular malformations in adults: the Scottish Intracranial Vascular Malformation Study (SIVMS). *Stroke* **34**:1163–1169, 2003
2. Andrade-Souza YM, Ramani M, Scora D, Tsao MN, ter-Brugge K, Schwartz ML: Embolization before radiosurgery reduces the obliteration rate of arteriovenous malformations. *Neurosurgery* **60**:443–452, 2007
3. ApSimon HT, Reef H, Phadke RV, Popovic EA: A population-based study of brain arteriovenous malformation: long-term treatment outcomes. *Stroke* **33**:2794–2800, 2002
4. Brown RD Jr, Wiebers DO, Forbes G, O'Fallon WM, Piepgras DG, Marsh WR, et al: The natural history of unruptured intracranial arteriovenous malformations. *J Neurosurg* **68**:352–357, 1988
5. Brown RD Jr, Wiebers DO, Torner JC, O'Fallon WM: Inci-

dence and prevalence of intracranial vascular malformations in Olmsted County, Minnesota, 1965 to 1992. *Neurology* **46**:949–952, 1996

6. Chang SD, Shuster DL, Steinberg GK, Levy RP, Frankel K: Stereotactic radiosurgery of arteriovenous malformations: pathologic changes in resected tissue. *Clin Neuropathol* **16**:111–116, 1997
7. Cockroft KM: Unruptured brain arteriovenous malformations should be treated conservatively: no. *Stroke* **38**:3310–3311, 2007 (Letter)
8. da Costa L, Wallace MC, Ter Brugge KG, O'Kelly C, Wilinsky RA, Tymianski M: The natural history and predictive features of hemorrhage from brain arteriovenous malformations. *Stroke* **40**:100–105, 2009
9. Flickinger JC, Kondziolka D, Lunsford LD, Kassam A, Phuong LK, Liscak R, et al: Development of a model to predict permanent symptomatic postradiosurgery injury for arteriovenous malformation patients. *Int J Radiat Oncol Biol Phys* **46**:1143–1148, 2000
10. Flickinger JC, Kondziolka D, Pollock BE, Maitz AH, Lunsford LD: Complications from arteriovenous malformation radiosurgery: multivariate analysis and risk modeling. *Int J Radiat Oncol Biol Phys* **38**:485–490, 1997
11. Graf CJ, Perret GE, Torner JC: Bleeding from cerebral arteriovenous malformations as part of their natural history. *J Neurosurg* **58**:331–337, 1983
12. Hartmann A, Mast H, Mohr JP, Pile-Spellman J, Connolly ES, Sciacca RR, et al: Determinants of staged endovascular and surgical treatment outcome of brain arteriovenous malformations. *Stroke* **36**:2431–2435, 2005
13. Hartmann A, Stapf C, Hofmeister C, Mohr JP, Sciacca RR, Stein BM, et al: Determinants of neurological outcome after surgery for brain arteriovenous malformation. *Stroke* **31**:2361–2364, 2000
14. Hillman J: Population-based analysis of arteriovenous malformation treatment. *J Neurosurg* **95**:633–637, 2001
15. Jessurun GA, Kamphuis DJ, van der Zande FH, Nossent JC: Cerebral arteriovenous malformations in The Netherlands Antilles. High prevalence of hereditary hemorrhagic telangiectasia-related single and multiple cerebral arteriovenous malformations. *Clin Neurol Neurosurg* **95**:193–198, 1993
16. Lawton MT, Du R, Tran MN, Achrol AS, McCulloch CE, Johnston SC, et al: Effect of presenting hemorrhage on outcome after microsurgical resection of brain arteriovenous malformations. *Neurosurgery* **56**:485–493, 2005
17. Lax I, Karlsson B: Prediction of complications in gamma knife radiosurgery of arteriovenous malformation. *Acta Oncol* **35**:49–55, 1996
18. Mohr JP, Moskowitz AJ, Stapf C, Hartmann A, Lord K, Marshall SM, et al: The ARUBA trial: current status, future hopes. *Stroke* **41**:e537–e540, 2010
19. Mounayer C, Hammami N, Pletin M, Spelle L, Benndorf G, Kessler I, et al: Nidal embolization of brain arteriovenous malformations using Onyx in 94 patients. *AJNR Am J Neuroradiol* **28**:518–523, 2007
20. Ondra SL, Troupp H, George ED, Schwab K: The natural history of symptomatic arteriovenous malformations of the brain: a 24-year follow-up assessment. *J Neurosurg* **73**:387–391, 1990
21. Pollock BE, Flickinger JC, Lunsford LD, Bissonette DJ, Kondziolka D: Factors that predict the bleeding risk of cerebral arteriovenous malformations. *Stroke* **27**:1–6, 1996
22. Pollock BE, Flickinger JC, Lunsford LD, Maitz A, Kondziolka D: Factors associated with successful arteriovenous malformation radiosurgery. *Neurosurgery* **42**:1239–1247, 1998
23. Pollock BE, Kondziolka D, Flickinger JC, Patel AK, Bissonette DJ, Lunsford LD: Magnetic resonance imaging: an accurate method to evaluate arteriovenous malformations after stereotactic radiosurgery. *J Neurosurg* **85**:1044–1049, 1996



24. Saatci I, Geyik S, Yavuz K, Cekirge HS: Endovascular treatment of brain arteriovenous malformations with prolonged intranidal Onyx injection technique: long-term results in 350 consecutive patients with completed endovascular treatment course. Clinical article. **J Neurosurg** **115**:78–88, 2011
25. Schlienger M, Atlan D, Lefkopoulos D, Merienne L, Touboul E, Missir O, et al: Linac radiosurgery for cerebral arteriovenous malformations: results in 169 patients. **Int J Radiat Oncol Biol Phys** **46**:1135–1142, 2000
26. Schneider BF, Eberhard DA, Steiner LE: Histopathology of arteriovenous malformations after gamma knife radiosurgery. **J Neurosurg** **87**:352–357, 1997
27. Sirin S, Kondziolka D, Niranjan A, Flickinger JC, Maitz AH, Lunsford LD: Prospective staged volume radiosurgery for large arteriovenous malformations: indications and outcomes in otherwise untreatable patients. **Neurosurgery** **58**:17–27, 2006
28. Spetzler RF, Martin NA: A proposed grading system for arteriovenous malformations. **J Neurosurg** **65**:476–483, 1986
29. Stapf C, Mast H, Sciacca RR, Berenstein A, Nelson PK, Gobin YP, et al: The New York Islands AVM Study: design, study progress, and initial results. **Stroke** **34**:e29–e33, 2003
30. Stapf C, Mast H, Sciacca RR, Choi JH, Khaw AV, Connolly ES, et al: Predictors of hemorrhage in patients with untreated brain arteriovenous malformation. **Neurology** **66**:1350–1355, 2006
31. Stapf C, Mohr JP: Unruptured brain arteriovenous malformations should be treated conservatively: yes. **Stroke** **38**:3308–3309, 2007
32. Stapf C, Mohr JP, Choi JH, Hartmann A, Mast H: Invasive treatment of unruptured brain arteriovenous malformations is experimental therapy. **Curr Opin Neurol** **19**:63–68, 2006
33. Steiner L, Lindquist C, Adler JR, Torner JC, Alves W, Steiner M: Clinical outcome of radiosurgery for cerebral arteriovenous malformations. **J Neurosurg** **77**:1–8, 1992
34. van Rooij WJ, Sluzewski M, Beute GN: Brain AVM embolization with Onyx. **AJNR Am J Neuroradiol** **28**:172–178, 2007
35. Wedderburn CJ, van Beijnum J, Bhattacharya JJ, Counsell CE, Papanastassiou V, Ritchie V, et al: Outcome after interventional or conservative management of unruptured brain arteriovenous malformations: a prospective, population-based cohort study. **Lancet Neurol** **7**:223–230, 2008
36. Wegner RE, Oysul K, Pollock BE, Sirin S, Kondziolka D, Niranjan A, et al: A modified radiosurgery-based arteriovenous malformation grading scale and its correlation with outcomes. **Int J Radiat Oncol Biol Phys** **79**:1147–1150, 2011

---

Manuscript submitted June 22, 2012.

Accepted February 13, 2013.

Please include this information when citing this paper: published online March 26, 2013; DOI: 10.3171/2013.2.JNS121239.

Address correspondence to: Jason Sheehan, M.D., Ph.D., University of Virginia, Department of Neurological Surgery, P.O. Box 800212, Charlottesville, Virginia 22908. email: jps2f@virginia.edu.