



**Decompressive Surgery in Cerebrovenous Thrombosis : A Multicenter Registry
and a Systematic Review of Individual Patient Data**

José M. Ferro, Isabelle Crassard, Jonathan M. Coutinho, Patrícia Canhão, Fernando Barinagarrementeria, Brett Cucchiara, Laurent Derex, Christoph Lichy, Jaime Masjuan, Ayrton Massaro, Gonzalo Matamala, Sven Poli, Mohammad Saadatnia, Erwin Stolz, Miguel Viana-Baptista, Jan Stam, Marie-Germaine Bousser and Second International Study on Cerebral Vein and Dural Sinus Thrombosis (ISCVT 2) Investigators

Stroke 2011, 42:2825-2831: originally published online July 28, 2011

doi: 10.1161/STROKEAHA.111.615393

Stroke is published by the American Heart Association, 7272 Greenville Avenue, Dallas, TX 75214
Copyright © 2011 American Heart Association. All rights reserved. Print ISSN: 0039-2499. Online
ISSN: 1524-4628

The online version of this article, along with updated information and services, is
located on the World Wide Web at:
<http://stroke.ahajournals.org/content/42/10/2825>

Subscriptions: Information about subscribing to Stroke is online at
<http://stroke.ahajournals.org/subscriptions/>

Permissions: Permissions & Rights Desk, Lippincott Williams & Wilkins, a division of Wolters
Kluwer Health, 351 West Camden Street, Baltimore, MD 21202-2436. Phone: 410-528-4050. Fax:
410-528-8550. E-mail:
journalpermissions@lww.com

Reprints: Information about reprints can be found online at
<http://www.lww.com/reprints>

Decompressive Surgery in Cerebrovenous Thrombosis

A Multicenter Registry and a Systematic Review of Individual Patient Data

José M. Ferro, MD, PhD; Isabelle Crassard, MD; Jonathan M. Coutinho, MD; Patrícia Canhão, MD, PhD; Fernando Barinagarrementeria, MD; Brett Cucchiara, MD; Laurent Derex, MD; Christoph Lichy, MD, MSc; Jaime Masjuan, MD; Ayrton Massaro, MD; Gonzalo Matamala; Sven Poli, MD; Mohammad Saadatian, MD; Erwin Stolz, MD; Miguel Viana-Baptista, MD, PhD; Jan Stam, MD, PhD; Marie-Germaine Bousser, MD, PhD; Second International Study on Cerebral Vein and Dural Sinus Thrombosis (ISCVT 2) Investigators

Background and Purpose—Herniation attributable to unilateral mass effect is the major cause of death in cerebral venous thrombosis (CVT). Decompressive surgery may be lifesaving in these patients.

Methods—Retrospective registry of cases of acute CVT treated with decompressive surgery (craniectomy or hematoma evacuation) in 22 centers and systematic review of all published cases of CVT treated with decompressive surgery. The primary outcome was the score on the modified Rankin Scale (mRS) score at last follow-up, dichotomized between favorable (mRS score, 0–4) and unfavorable outcome (mRS score, 5 or death). Secondary outcomes were complete recovery (mRS score 0–1), independence (mRS score, 0–2), severe dependence (mRS score, 4–5), and death at last available follow-up.

Results—Sixty-nine patients were included and 38 were from the registry. Decompressive craniectomy was performed in 45 patients, hematoma evacuation was performed in 7, and both interventions were performed in 17 patients. At last follow-up (median, 12 months) only 12 (17.4%) had an unfavorable outcome. Twenty-six (37.7%) had mRS score 0 to 1, 39 (56.5%) had mRS score 0 to 2, 4 (5.8%) were alive with mRS score 4 to 5, and 11 (15.9%) patients died. Three of the 9 patients with bilateral fixed pupils recovered completely. Comatose patients were less likely to be independent (mRS score 0–2) than noncomatose patients (45% versus 84%; $P=0.003$). Patients with bilateral lesions were more likely to have unfavorable outcomes (50% versus 11%; $P=0.004$) and to die (42% versus 11%; $P=0.025$).

Conclusions—In CVT patients with large parenchymal lesions causing herniation, decompressive surgery was lifesaving and often resulted in good functional outcome, even in patients with severe clinical conditions. (*Stroke*. 2011;42:2825–2831.)

Key Words: cerebral venous thrombosis ■ decompressive surgery ■ intracranial hemorrhage ■ neurosurgery

Although $\approx 75\%$ of patients with cerebral venous thrombosis (CVT)¹ have a favorable outcome, a minority (4%)² may die in the acute phase. Herniation attributable to unilateral mass effect produced by large edematous venous infarctions or parenchymal hemorrhages is the major cause of acute death in CVT.² In arterial ischemic stroke, decompressive surgery reduces mortality and increases the number of patients with a favorable functional outcome, as demonstrated in recent randomized controlled trials,³ namely in hemicrani-

ectomy, in patients with large cerebellar infarcts, and in malignant middle cerebral infarcts causing herniation. Decompressive surgery may be lifesaving also in CVT patients with lesions causing mass effect and clinical deterioration. However, the information on decompressive surgery in CVT is limited to case reports and results from small series from referral centers.^{4,5} Also, the characteristics of CVT patients who benefit from decompressive surgery are not known. The aim of this study was to collect the best available information

Received February 1, 2011; accepted April 5, 2011.

From the Department of Neurosciences (J.M.F., P.C.), Hospital Santa Maria, University of Lisbon, Lisbon, Portugal; Department of Neurology (I.C., M.G.B.), Hôpital Lariboisière, Paris, France; Department of Neurology (J.M.C., J.S.), Academic Medical Centre, Amsterdam, the Netherlands; Department of Neurology (F.B.), Instituto Nacional de Neurología y Neurocirugía, Mexico City, Mexico; Department of Neurology (B.C.), University of Pennsylvania Medical Center, Philadelphia, PA; Department of Neurology (L.D.), Neurological Hospital, Creatis UMR CNRS 5515, Inserm U, Lyon, France; Department of Neurology (C.L.), Memmingen Hospital, Germany; Stroke Unit (J.M.), Department of Neurology, Hospital Ramón y Cajal, Madrid, Spain; Department of Neurology (A.M.), University of Kentucky, Lexington, KY; Sección de Neurología (G.M.), Servicio de Neurología, Hospital Naval Almirante Nef, Viña del Mar, Chile; Department of Neurology (S.P.), University of Heidelberg, Heidelberg, Germany; Department of Neurology (M.S.), Isfahan Neurosciences Research Center, Isfahan University of Medical Sciences, Isfahan, Iran; Department of Neurology (E.S.), Justus-Liebig University, Giessen, Germany; Department of Neurology (M.V.B.), Hospital Egas Moniz, Universidade Nova de Lisboa, Lisbon, Portugal.

Correspondence to José M. Ferro, MD, PhD, Department of Neurosciences, Hospital Santa Maria, 1649-035 Lisboa, Portugal. E-mail jmferro@fm.ul.pt
© 2011 American Heart Association, Inc.

Stroke is available at <http://stroke.ahajournals.org>

DOI: 10.1161/STROKEAHA.111.615393

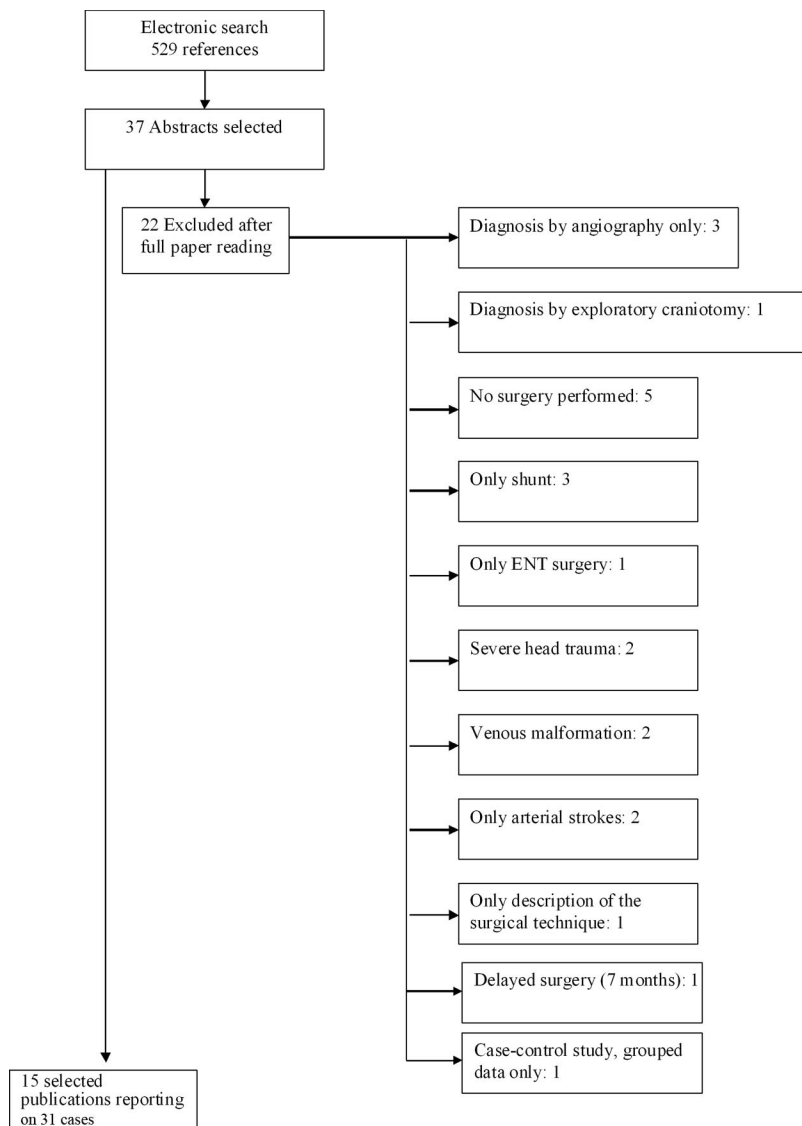


Figure 1. Flow chart of the literature review.

on the outcome and on predictors of outcome of CVT patients who underwent decompressive surgery in the acute phase by performing a multicenter registry and a systematic review of all cases available in the literature.

Patients and Methods

We invited 63 investigators with an interest in CVT/neurointensive care, including the investigators of the International Study on Cerebral Vein and Dural Sinus Thrombosis,¹ to report all cases of acute CVT treated by decompressive surgery (craniectomy or hematoma evacuation) in their institutions since 1998 (year when International Study on Cerebral Vein and Dural Sinus Thrombosis was initiated). Investigators completed a case report form describing patient demographics, clinical (Glasgow Coma Scale, pupils, and aphasia) and neuroimaging findings, and timing and type of surgery and outcome as evaluated by the modified Rankin Scale (mRS) at discharge, 6, 12, 24 months, or last available follow-up. To reduce selection bias and to avoid overlapping cases with the systematic review, we only included in the registry unpublished cases.

Additionally, we performed a systematic review of individual patient data of all published cases of CVT treated by decompressive surgery (craniectomy or hematoma evacuation). We searched MEDLINE, PubMed, and Cochrane electronic databases up to October 2010 without language restrictions. Key words and search

strategy are described in the Appendix. We completed the search by manually searching reference lists of all retrieved articles. All retrieved titles and abstracts were reviewed independently by 2 of the investigators (J.F. and P.C.). Full publications were obtained based on the titles or abstracts selected by at least 1 of the reviewers. Full publications were reviewed to select the studies to be included in the review. Inclusion criteria were reports describing: (1) patients with cerebral venous thrombosis; (2) patients with parenchymal lesions (ischemic or hemorrhagic); (3) cases documented by CT or MR; (4) cases treated by decompressive craniectomy (unilateral, bilateral, or posterior fossa) or hematoma evacuation or both; and (5) patients with follow-up information on survival and disability, at least at hospital discharge. CVT diagnosed by angiography only were not included because we needed information on the presence and type of parenchymal lesions. To avoid confounding by indication, patients who had CVT diagnosed at exploratory neurosurgery, CVT associated with severe head trauma, or other intracranial disease (ruptured arteriovenous malformation or development venous anomaly) for whom decompressive surgery could have been indicated were excluded. We only included publications that allowed extraction of individual patient data. Studies with only grouped data about outcomes were excluded, but the available information was analyzed in a sensitivity analysis. We also checked for repeated publications and excluded duplicated cases. From each case report, data were extracted and entered in the same standard form used for the

Table 1. Baseline Characteristics and Outcomes of the Patients Included in the Registry and in the Systematic Review

	Registry	Review	All Cases	<i>P</i>
No. of cases	38	31	69	
Baseline characteristics				
Females (%)	29 (76.3)	23 (74.2)	52 (75.4)	0.84
Median age	43	40	42	0.77
Age range (y)	20–66	15–68	15–68	
Glasgow Coma Scale score before surgery				
<9	25 (65.8)	24 (80.0)*	49 (72.1)	0.20
9–14	13 (34.2)	6 (20.0)	19 (27.5)	
Fixed dilated pupils (%)				
None	16 (47.1)†	10 (37.0)†	26 (42.6)	0.65
Unilateral	14 (41.2)	12 (44.4)	26 (42.6)	
Bilateral	4 (11.8)	5 (18.5)	9 (14.8)	
Aphasia (%)	17 (44.7)	11 (39.3)‡	28 (42.4)	0.66
Parenchymal lesions (%)				
Unilateral	32 (84.2)	25 (80.6)	57 (82.6)	0.70
Bilateral	6 (15.8)	6 (19.4)	12 (17.4)	
Hemorrhagic	32 (84.2)	30 (96.8)	62 (89.9)	0.41
Surgery				
Median interval (d)				
Symptom onset to surgery	3.5	5	4	0.41
Diagnosis to surgery	2	1	2	0.93
Worsening to surgery	1	0	1	0.11
Type of surgery (%)				
Decompressive craniectomy	23 (60.5)	22 (71.0)	45 (65.2)	0.04
Right hemisphere	11 (28.9)	10 (32.3)	21 (30.4)	
Left hemisphere	9 (23.7)	11 (35.5)	20 (28.9)	
Bilateral	...	2 (6.5)	2 (3.2)	
Posterior fossa	3 (7.9)	...	3 (4.3)	
Hematoma evacuation (%)	7 (18.4)	0 (0)	7 (10.1)	
Right hemisphere	4 (10.5)	...	4 (5.8)	
Left hemisphere	3 (7.9)	...	3 (4.3)	
Bilateral	
Posterior fossa	
Both types of surgery (%)	8 (21.1)	9 (29.0)	17 (24.6)	
Right hemisphere	4 (10.5)	3 (9.7)	7 (10.1)	
Left hemisphere	4 (10.5)	5 (16.1)	9 (13.0)	
Bilateral	...	1 (3.2)	1 (1.4)	
Posterior fossa	
Outcome (%)				
Median follow-up (mo)	14.5	12	12	0.52
Complete recovery (mRS score 0–1)	12 (31.6)	14 (45.2)	26 (37.7)	0.25
Independence (mRS score 0–2)	21 (55.3)	18 (58.1)	39 (56.5)	0.82
Independence (mRS score 0–2)§		26 (61.9)	47 (58.8)	
Severe dependence (mRS score 4–5)	3 (7.9)	1 (3.2)	4 (5.8)	0.76
Death (mRS score 6)	7 (18.4)	4 (12.9)	11 (15.9)	0.53
Death (mRS score 6)§		7 (16.6)	14 (17.5)	
Unfavorable outcome (mRS score 5–6)	8 (21.1)	4 (12.9)	12 (17.4)	0.37

P is comparison between registry and review.

mRS indicates Modified Rankin Scale.

Missing data in 1,* 4,† and 3‡ cases.

§Sensitivity analysis including the excluded series by Lath et al (11 patients).⁷

retrospective registry. Authors were contacted to provide additional information on missing or unclear data. Outcome was registered using the mRS at discharge, 6, 12, and 24 months, or last follow-up. When other scales were used or only descriptive information on outcome was available, transformation into mRS grades was performed independently by 2 observers (J.F., I.C., or J.C.) and a consensus was reached if grading did not coincide.

The primary outcome was the score on the mRS at last follow-up dichotomized between favorable (mRS score, 0–4) and unfavorable outcome (mRS score, 5 or death). Secondary outcomes were complete recovery (mRS score, 0–1), independence (mRS score, 0–2), severe dependency (mRS score, 4–5), and death at last available follow-up. Prognostic variables were age, Glasgow Coma Scale, fixed pupils, side, localization and type of lesion, interval from onset to surgery, and type of surgery.

We calculated descriptive statistics for baseline variables and outcomes of individual patient data using frequencies and medians and ranges of individual data from all included cases, respectively, for categorical and continuous variables. Associations between prognostic variables and outcomes were calculated using χ^2 statistics, with continuity correction when needed. Recall and publication bias and heterogeneity between studies were evaluated by comparing outcomes of cases retrieved from cohorts or prospective registries versus all the others, published versus nonpublished cases (registry), between centers reporting ≤ 2 versus > 2 cases, and between cases undergoing operation before 2006 and in 2006 or after (median of the years when surgery was performed).

SPSS version 17 software was used. $P < 0.05$ was considered significant. We did not correct for multiple comparisons.⁶

Results

Registry

Thirty-eight cases from 22 centers were registered (29 females; median age, 43 years). Seven other investigators declared that decompressive surgery was never performed in their center in patients with acute CVT. The majority of the registered patients had a severe condition, with early signs of transtentorial herniation; 25 (65.8%) patients were comatose before surgery and 18 (53.0%) had dilated fixed pupils, which were bilateral in 4. The majority of the lesions were hemorrhagic (84.2%). Decompressive craniectomy was performed in 23 (60.5%) patients and hematoma evacuation was performed in 7 (18.4%). Eight patients (21.1%) underwent both types of surgery.

Systematic Review

From the literature search (Figure 1), we included 15 publications fulfilling the inclusion and exclusion criteria reporting on 31 patients (23 females; median age, 40 years).^{4,5,8–20} Twenty-four (80.0%) patients were comatose before surgery; 17 (62.9%) had dilated fixed pupils (bilateral in 5). Almost all lesions (96.8%) were hemorrhagic. Decompressive craniectomy was performed in all patients; it was in 9 (29.0%) in combination with hematoma evacuation. One excluded study⁷ presented grouped data only: 11 acute CVT patients with Glasgow Coma Scale < 9 and large hemispheric lesions were treated by decompressive surgery; 6 of these were treated within 24 hours of admission.

Although a larger proportion of cases included in the review had coma, asymmetrical pupils, and hemorrhagic lesions, these differences did not reach the significance or statistical trend level. Hematoma evacuation alone was never reported in the cases included in the review and hematoma evacuation, alone or in combination with decompressive

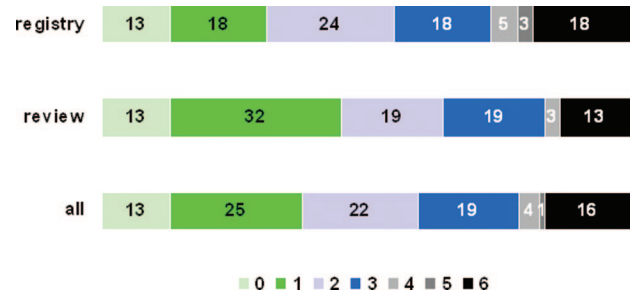


Figure 2. Modified Rankin Scale (mRS) grades distribution (percentages) at last follow-up.

craniectomy, was performed significantly ($P < 0.04$) less often in the review cases.

Outcome

Patients were followed-up for a median of 14.5 months; 27 (71.1%) were followed-up by direct interview. Seven (18.4%) patients who underwent operation died. At last follow-up, 12 (31.6%) had recovered completely (mRS score, 0–1), whereas 8 (21.1%) had an unfavorable outcome (mRS score, 5–6), including 7 (18.4%) deaths. Only 3 (7.9%) were alive with mRS score 4 to 5.

At last follow-up (median, 12 months), 14 (45.2%) patients recovered to mRS score 0 to 1. Four (12.9%) had an unfavorable outcome (4 deaths). Only 1 (3.2%) patient was alive with severe dependency (mRS score, 4). In the excluded publication with only grouped data, 3 (27%) patients died, but 8 (73%) had mRS score 0 to 2 at the end of a mean follow-up of 7.4 months.

Table 1 shows the distribution of the patients from the registry, from the systematic review, and of all patients by the different outcomes. There were no significant differences in any of the outcomes between patients included in the registry and in the review (Figure 2, Table 1).

There was considerable functional improvement from hospital discharge to last follow-up. Of 22 patients who were discharged with severe dependency (mRS score, 4–5), 4 (18.2%) recovered completely to mRS score 0 to 1 and only 3 (13.6%) remained severely dependent.

Table 2 shows the distribution of the outcomes according to potential predictors and confounders. Several patients with severe conditions before surgery had complete recovery or were independent at last follow-up. Approximately one-third of comatose patients recovered completely. Three out of 9 patients with bilateral fixed pupils recovered completely. The 2 patients who had bilateral surgery were alive and independent. All 3 patients who had decompressive posterior fossa surgery recovered to mRS score 0 or 1.

Fewer patients with Glasgow Coma Scale score < 9 had mRS score 0 to 2 at final follow-up compared with patients with Glasgow Coma Scale score ≥ 9 (44.9% versus 84.2%; $P = 0.003$). Patients with bilateral lesions were more likely to have unfavorable outcome at the end of follow-up (50.0% versus 10.5%; $P = 0.004$) and to die (41.7% versus 10.5%; $P = 0.025$). None of the other variables was predictive of any of the outcomes.

Table 2. Outcome at Last Follow-Up by Prognostic Factors

	n	Outcome (mRS), N (%)				
		0–1	0–2	4–5	5–6	6
Age (y)						
≤60	64	24 (37.5)	36 (56.2)	4 (6.2)	12 (18.8)	11 (17.2)
>60	5	2 (40.0)	3 (60.0)	0 (0)	0 (0)	0 (0)
Glasgow Coma Scale score*						
<9	49	17 (34.7)	22 (44.9)¶	4 (8.2)	9 (18.4)	8 (16.3)
≥9	19	9 (47.4)	16 (84.2)	0 (0)	3 (15.8)	3 (15.8)
Fixed dilated pupils†						
None	26	9 (34.6)	18 (69.2)	0 (0)	4 (15.4)	4 (15.4)
Unilateral	26	11 (42.3)	12 (46.2)	2 (7.7)	5 (19.2)	5 (19.2)
Bilateral	9	3 (33.3)	4 (44.4)	2 (22.2)	2 (22.2)	1 (11.1)
Aphasia‡						
	28	12 (42.9)	18 (64.3)	2 (7.1)	4 (14.3)	3 (10.7)
Parenchymal lesions						
Unilateral	57	22 (38.6)	35 (61.4)	3 (5.3)	6 (10.5)	6 (10.5)
Bilateral	12	4 (33.3)	4 (33.3)	1 (8.3)	6 (50.0)	5 (41.7)**
Hemorrhagic	62	22 (35.5)	34 (54.8)	2 (3.2)	11 (17.7)	11 (17.7)
Interval diagnosis, surgery§						
0–1 d	43	15 (34.9)	23 (53.5)	2 (4.7)	10 (23.3)	10 (23.3)
≥2 d	22	10 (45.5)	13 (59.1)	2 (9.1)	2 (9.1)	1 (4.5)
Decompressive craniectomy						
Unilateral	45	17 (37.8)	25 (55.6)	2 (4.4)	11 (24.4)	10 (22.2)
Bilateral	41	14 (34.1)	21 (51.2)	2 (4.9)	11 (26.8)	10 (24.4)
Posterior fossa	1	0 (0)	1 (100.0)	0 (0)	0 (0)	0 (0)
Hematoma evacuation						
	3	3 (100.0)	3 (100.0)	0 (0)	0 (0)	0 (0)
Both surgeries						
Unilateral	17	7 (41.2)	9 (52.9)	2 (11.8)	1 (5.9)	1 (5.9)
Bilateral	16	6 (37.5)	8 (50.0)	2 (12.5)	1 (6.2)	1 (6.2)
Year of surgery*						
Before 2006	34	13 (38.2)	20 (58.8)	3 (8.8)	6 (17.6)	6 (17.6)
2006 or after	34	13 (38.2)	19 (55.9)	1 (2.9)	5 (14.7)	4 (11.8)
N cases						
0–2	33	10 (30.3)	18 (54.5)	1 (3.0)	6 (18.2)	6 (18.2)
>2	36	16 (44.4)	21 (58.3)	3 (8.3)	6 (16.7)	5 (13.9)

mRS indicates Modified Rankin Scale; n, number with variable condition; %, number with outcome/number with variable condition.

Missing data in 1, * 8, † 3, ‡ and 4§ cases.

¶ $P=0.003$.

|| $P=0.004$.

** $P=0.025$.

All the other comparisons had $P>0.05$.

Sensitivity Analysis

Cases retrieved from cohorts or prospective registries were more likely to recover completely (12/20 [60%] versus 14/49 [28.6%]; $P=0.02$). There were no significant differences for any of the outcomes between published versus nonpublished cases (registry; Table 1), between centers reporting ≤ 2 versus > 2 cases, and between cases undergoing operation before 2006 and in 2006 or after (median of the years when surgery was performed; Table 2). The inclusion of the excluded study⁷ with grouped data only did not significantly modify the rates of death or independent survival (Table 2).

Discussion

This multinational registry of decompressive surgery (decompressive craniectomy, hematoma evacuation, or both) in patients with acute CVT and parenchymal lesions with impending herniation shows that decompressive surgery was lifesaving and often resulted in good functional outcome, even in older patients or in those in coma or with aphasia, bilateral lesions, or fixed pupils. Eighteen percent of the CVT patients in the registry who underwent operation died, but only 8% were severely dependent at last follow-up. The results of the registry were confirmed by a systematic review

of the literature of published reports of acute CVT patients who had decompressive surgery with similar outcome results. The outcomes were similar after decompressive craniectomy, hematoma evacuation, or both interventions. Although the numbers are small, the outcome was good for posterior fossa craniectomy and independent survival was achieved in patients who had bilateral cranial vault surgery. Practice did not seem to change the results of surgery significantly, because the outcomes were not influenced by the year when surgery was performed or by the number of reported patients who underwent operation. One-third of the patients with bilateral fixed pupils before surgery recovered completely. Comatose patients and those with bilateral lesions were more likely to have an unfavorable outcome; nevertheless, complete recovery was observed in approximately one-third of such patients. Aphasia did not influence outcome.

The registry was retrospective, which raises the possibility of selection and recall bias. However, the fact that acute CVT patients who are treated surgically are rare patients with dramatic presentations probably diminishes the risk of recall bias. To reduce selection bias and to avoid overlapping cases with the systematic review, we only included in the registry nonpublished cases. The inclusion of patients from several hospitals and different countries also decreases selection bias. To encourage participation and limit the amount of work of the local investigators, we did not collect information on the complications of surgery. The reliability of collecting this information retrospectively also would be limited. We also did not study outcomes other than recovery, dependency, or death, such as patient preference, cognitive and psychiatric outcomes, or employment status.

The systematic review of published cases yielded results analogous to those of the registry. In addition, baseline characteristics and distribution of prognostic factors were similar in the review and in the registry. Published cases predominantly report decompressive craniectomy, whereas in the registry several cases of hematoma evacuation were retrieved. This indicates an obvious publication bias toward decompressive craniectomy, perhaps because hematoma evacuation is considered a routine lifesaving procedure for intracerebral hematoma with eminent herniation. Outcomes were comparable in single or dual published cases reports or in larger case series, a result that argues against publication bias. The inclusion of a study with grouped data only did not modify the outcome results.

A pooled analysis of 93 patients from 3 randomized controlled trials of decompressive hemicraniectomy in malignant middle cerebral artery infarctions showed that the surgery reduces case fatality and poor outcome in patients aged 60 years old or younger who are treated within 48 hours of stroke onset.³ The outcomes after decompressive surgery in CVT in our present study are much better than those observed in the pooled analysis of hemicraniectomy for ischemic arterial stroke in terms of mortality (16% versus 22%), severe dependence (mRS score, 4–5; 6% versus 35%), and especially complete recovery (mRS score, 0–1; 38% versus 0%). Although in arterial ischemic stroke patients with bilateral dilated fixed pupils were excluded from hemicraniectomy trials, we found complete recovery in one-third of

similar CVT patients who underwent operation. In arterial stroke, decompressive surgery fails to improve functional outcome if performed later than 48 hours²¹ and the prognosis is significantly worse for patients older than 60 years of age.²² In CVT, although there are fewer patients who undergo operation, no influence of time to surgery or age could be detected in our data.

The encouraging results we observed reflect the overall good survival and functional outcome of patients with CVT, once acute death attributable to cerebral herniation is prevented.^{1,2,23} Many of the parenchymal lesions in CVT are not true infarcts, but rather are areas of mixed vasogenic and cytotoxic edema with or without hemorrhagic transformation.^{24,25} Many of these lesions are fully reversible, a fact that further contributes to a favorable prognosis.²⁵

These results encourage the use of decompressive surgery as a lifesaving procedure in selected CVT patients. A severe neurological condition, such as coma, bilateral fixed pupils, or bilateral lesions, should not discourage surgery, because at least one-third of such patients can have a good recovery.

As discussed, weak points of our study are the retrospective design of the registry and the possibility of publication bias in the systematic review. Therefore, the results of this retrospective study and systematic review may overestimate the efficacy and safety of decompressive surgery and need confirmation in a prospective registry. Such a registry should also evaluate the complications of surgery, neuropsychiatric, and psychosocial outcomes.

Appendix

List of International Study on Cerebral Vein and Dural Sinus Thrombosis 2 investigators who participated in this study, with number of patients included. Portugal: M. Viana Baptista, Almada and Lisboa, (2); J. Ferro, P. Canhão, Lisboa, (2); A.N. Pinto, Amadora (1); Spain: J. Masjuan, Madrid, (3); France: L. Derex, Lyon (1); B. Guillon, Nantes (1); I. Crassard, M.G. Bousser, Paris (2); J.C. Lacour, Nancy (3); Germany: C. Lichy, S. Polly, Heidelberg, (3); E. Stolz, Giessen (2); S. Kirsch, Munich (1); F. Weillbach, Wurzburg (1); S. Schwab, Erlanger (1); the Netherlands: J. Coutinho, J. Stam, Amsterdam (1); UK: R. Al-Shahi Salman, Edinburgh (1); Iran: M. Saadatnia, Isfahan (4); United States: B. Cucchiara, Philadelphia, PA (1); Mexico: J.L. Ruiz-Sandoval, Guadalajara (1); Chile: J. Matamala, Vina del Mar (2); Brazil: G. de Freitas, Rio de Janeiro (1); G. Dutra, A. Massaro, S. Paulo (2); R.C. Nogueira, Sao Paulo (1); R.A. Valiente, Sao Paulo (1).

Search Strategy

("intracranial embolism AND thrombosis") OR (intracranial thrombosis) OR (sinus thrombosis, intracranial) OR (intracranial embolism) OR (cerebral veins OR cavernous sinus OR cranial sinuses OR dura mater) AND (venous thrombosis OR thrombosis OR thromboembolism) OR (CVDST OR CVT) AND (decompression, surgical) OR (craniotomy) OR (neurosurgical procedures) OR (evacuation) OR (trephining) OR (decompress\$ OR craniectomy OR craniotomy OR hemicraniectomy) OR (hippocampectomy OR lobectomy) AND (Humans[Mesh]).

Acknowledgments

The authors acknowledge Wo Pfeilschifter and Naoki Kato (excluded case) for providing additional information on their cases.

Disclosures

None.

References

1. Ferro JM, Canhão P, Stam J, Bousser MG, Barinagarrementeria F, ISCVT Investigators. Prognosis of cerebral vein and dural sinus thrombosis: results of the International Study on Cerebral Vein and Dural Sinus Thrombosis (ISCVT). *Stroke*. 2004;35:664–670.
2. Canhão P, Ferro JM, Lindgren AG, Bousser MG, Stam J, Barinagarrementeria F, ISCVT Investigators. Causes and predictors of death in cerebral venous thrombosis. *Stroke*. 2005;36:1720–1725.
3. Vahedi K, Hofmeijer J, Juettler E, Vicaud E, George B, Algra A, et al; DECIMAL, DESTINY, and HAMLET investigators. Early decompressive surgery in malignant infarction of the middle cerebral artery: a pooled analysis of three randomised controlled trials. *Lancet Neurol*. 2007;6:215–222.
4. Théaudin M, Crassard I, Bresson D, Saliou G, Favrole P, Vahedi K, et al. Should decompressive surgery be performed in malignant cerebral venous thrombosis?: a series of 12 patients. *Stroke*. 2010;41:727–731.
5. Coutinho JM, Majoie CB, Coert BA, Stam J. Decompressive hemicraniectomy in cerebral sinus thrombosis: consecutive case series and review of the literature. *Stroke*. 2009;40:2233–2235.
6. Rothman KJ. No adjustments are needed for multiple comparisons. *Epidemiology*. 1990;1:43–46.
7. Lath R, Kumar S, Reddy R, Boola GR, Ray A, Prabhakar S, et al. Decompressive surgery for severe cerebral venous sinus thrombosis. *Neurol India*. 2010;58:392–397.
8. Barbati G, Dalla Montà G, Coletta R, Blasetti AG. Post-traumatic superior sagittal sinus thrombosis. Case report and analysis of the international literature. *Minerva Anesthesiol*. 2003;69:919–925.
9. Dohmen C, Galldiks N, Moeller-Hartmann W, Fink GR, Timmermann L. Sequential escalation of therapy in “malignant” cerebral venous and sinus thrombosis. *Neurocrit Care*. 2010;12:98–102.
10. Ebke M, Jürgens KU, Tomandl B, Merten U, Kastrup A. Surgical treatment of space occupying edema and hemorrhage due to cerebral venous thrombosis during pregnancy. *Neurocrit Care* 2010 Jun 4. [Epub ahead of print].
11. Lin HS, Lin JF, Chang CK, Tsai CC, Chen SJ. Cerebral sinus thrombosis with intracerebral hemorrhage in pregnancy: a case report. *Acta Neurol Taiwan*. 2008;17:189–193.
12. Stefani R, Latronico N, Cornali C, Rasulo F, Bollati A. Emergent decompressive craniectomy in patients with fixed dilated pupils due to cerebral venous and dural sinus thrombosis: report of three cases. *Neurosurgery*. 1999;45:626–629.
13. Weber J, Spring A. Unilateral decompressive craniectomy in left transverse and sigmoid sinus thrombosis. *Zentralbl Neurochir*. 2004;65:135–140.
14. Lanterna LA, Gritti P, Manara O, Grimod G, Bortolotti G, Biroli F. Decompressive surgery in malignant dural sinus thrombosis: report of 3 cases and review of the literature. *Neurosurg Focus*. 2009;26:E5.
15. Pfeilschifter W, Neumann-Haefelin T, Hattingen E, Singer OC. Cortical venous thrombosis after a diagnostic lumbar puncture. *Nervenarzt*. 2009;80:1219–1221.
16. Kuroki K, Taguchi H, Sumida M, Onda J. Dural sinus thrombosis in a patient with protein S deficiency—case report. *Neurol Med Chir (Tokyo)*. 1999;39:928–931.
17. Galarza M, Gazzeri R. Cerebral venous sinus thrombosis associated with oral contraceptives: the case for neurosurgery. *Neurosurg Focus*. 2009;27:E5.
18. Keller E, Pangalu A, Fandino J, Könti D, Yonekawa Y. Decompressive craniectomy in severe cerebral venous and dural sinus thrombosis. *Acta Neurochir Suppl*. 2005;94:177–183.
19. Armonda RA, Vo AH, Bell R, Neal C, Campbell WW. Multimodal monitoring during emergency hemicraniectomy for vein of Labbe thrombosis. *Neurocrit Care*. 2006;4:241–244.
20. Zeng L, Derex L, Maarrawi J, Dailler F, Cakmak S, Nighoghossian N, et al. Lifesaving decompressive craniectomy in ‘malignant’ cerebral venous infarction. *Eur J Neurol*. 2007;14:e27–e28.
21. Hofmeijer J, Kappelle LJ, Algra A, Amelink GJ, van Gijn J, van der Worp HB, HAMLET investigators. Surgical decompression for space-occupying cerebral infarction (the Hemicraniectomy After Middle Cerebral Artery infarction with Life-threatening Edema Trial [HAMLET]): a multicentre, open, randomised trial. *Lancet Neurol*. 2009;8:326–333.
22. Arac A, Blanchard V, Lee M, Steinberg GK. Assessment of outcome following decompressive craniectomy for malignant middle cerebral artery infarction in patients older than 60 years of age. *Neurosurg Focus*. 2009;26:E3.
23. Dentali F, Gianni M, Crowther MA, Ageno W. Natural history of cerebral vein thrombosis: a systematic review. *Blood*. 2006;108:1129–1134.
24. Ferro JM, Canhão P, Bousser MG, Stam J, Barinagarrementeria F, Stolz E, ISCVT Investigators. Cerebral venous thrombosis with nonhemorrhagic lesions: clinical correlates and prognosis. *Cerebrovasc Dis*. 2010;29:440–445.
25. Bousser MG, Ferro JM. Cerebral venous thrombosis: an update. *Lancet Neurol*. 2007;6:162–170.