

## Avoidance of wrong-level thoracic spine surgery: intraoperative localization with preoperative percutaneous fiducial screw placement

### Clinical article

\*CHEERAG D. UPADHYAYA, M.D., M.Sc.,<sup>1</sup> JAU-CHING WU, M.D.,<sup>1-4</sup> CYNTHIA T. CHIN, M.D.,<sup>5</sup> GOPALAKRISHNAN BALAMURALI, M.D., F.R.C.S.(SN),<sup>1</sup> AND PRAVEEN V. MUMMANENI, M.D.<sup>1</sup>

Departments of <sup>1</sup>Neurological Surgery and <sup>5</sup>Radiology, University of California, San Francisco, California; <sup>2</sup>Department of Neurosurgery, Neurological Institute, Taipei Veterans General Hospital; and <sup>3</sup>School of Medicine and <sup>4</sup>Institute of Pharmacology, National Yang-Ming University, Taipei, Taiwan

**Object.** The accurate intraoperative localization of the correct thoracic spine level remains a challenging problem in both open and minimally invasive spine surgery. The authors describe a technique of using preoperatively placed percutaneous fiducial screws to localize the area of interest in the thoracic spine, and they assess the safety and efficacy of the technique.

**Methods.** To avoid wrong-level surgery in the thoracic spine, the authors preoperatively placed a percutaneous 5-mm fiducial screw at the level of intended surgery using CT guidance. Plain radiographs and CT images with reconstructed views can then be referenced in the operating room to verify the surgical level, and the fiducial screw is easily identified on intraoperative fluoroscopy. The authors compared a group of 26 patients who underwent preoperative (often outpatient) fiducial screw placement prior to open or minimally invasive thoracic spine surgery to a historical group of 26 patients who had intraoperative localization with fluoroscopy alone.

**Results.** In the treatment group of 26 patients, no complications related to fiducial screw placement occurred, and there was no incidence of wrong-level surgery. In comparison, there were no wrong-level surgeries in the historical cohort of 26 patients who underwent mini-open or open thoracic spine surgery without placement of a fiducial screw. However, the authors found that the intraoperative localization fluoroscopy time was greatly reduced when a fiducial screw localization technique was employed.

**Conclusions.** The aforementioned technique for intraoperative localization is safe, efficient, and accurate for identifying the target level in thoracic spine exposures. The fiducial marker screw can be placed using CT guidance on an outpatient basis. There is a reduction in the amount of intraoperative fluoroscopy time needed for localization in the fiducial screw group. (DOI: 10.3171/2011.3.SPINE10445)

**KEY WORDS** • thoracic spine • fiducial screw • wrong level • intraoperative localization • percutaneous

THE intraoperative localization of thoracic vertebral levels remains a challenging problem. A recent questionnaire study by Mody et al.<sup>12</sup> found a high prevalence of wrong-level surgeries among spine surgeons with nearly 50% of surgeons performing a wrong-level surgery during their career. Correct-level spine surgery is an important patient safety and quality-of-care issue.<sup>5</sup> Several factors make the thoracic spine especially difficult for proper target level localization including osteoporosis, obesity, scapular/humeral shadow, anatomical variations in the number of thoracic rib-bearing vertebrae, and the distance from occipitocervical or lumbosacral landmarks. Various techniques have been described for localization in the thoracic spine.<sup>8,13,14,18</sup> We sought to determine if the preoperative placement of a fiducial marker screw for spinal localization was a safe and effective method of preventing wrong-level surgery.

\* Drs. Upadhyaya and Wu contributed equally to this work.

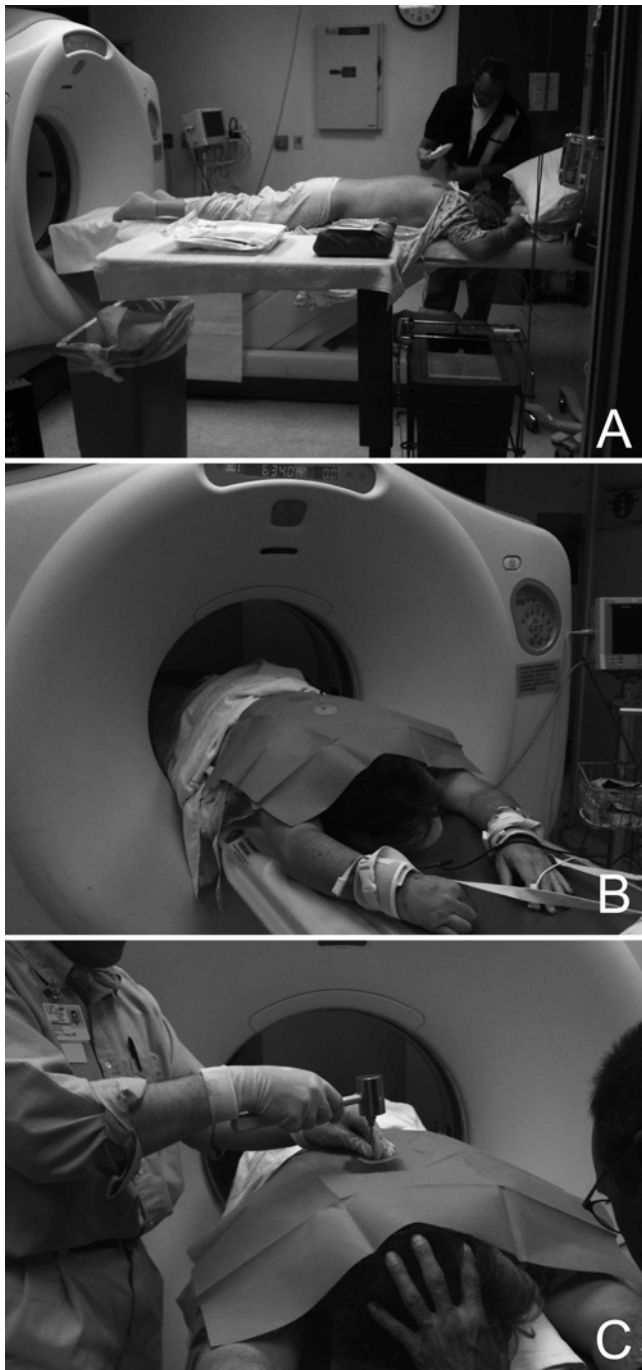
### Methods

We conducted a retrospective analysis of patients who underwent minimally invasive or open thoracic spine surgery performed by the senior author (P.V.M.) in a single center. We compared 26 patients with preoperatively placed fiducial markers and a historical cohort of 26 patients in whom intraoperative localization was performed with fluoroscopy alone. The characteristics of the patients are described in Table 1. Data were analyzed with the STATA 9 software package. A value of  $p \leq 0.05$  was considered statistically significant.

#### *Fiducial Screw Placement Technique*

On an outpatient basis, the fiducial screws are placed in patients after induction of conscious sedation. Patients are placed in the prone position (Fig. 1A). Initial helically acquired axial CT scans through the targeted region are obtained (2.5-mm thickness). The appropriate trajectory for fiducial screw placement is planned, and the skin entry

## Percutaneous fiducial screw placement for localization



**FIG. 1.** **A:** Patient positioned prone for the procedure. **B:** Skin marker placed at the level of interest and CT scan acquired. **C:** Fiducial marker placed and implanted on the vertebra.

site for the fiducial placement is identified (Fig. 1B). Utilizing the percutaneous fiducial screw system and under CT guidance, the trocar is advanced through the subcutaneous tissues to the target (Fig. 1C). A 2 × 5-mm stainless-steel fiducial screw is attached to the screwdriver and inserted in a coaxial fashion through the trocar and implanted under CT guidance at the junction of the vertebral transverse process, pedicle, and lamina of the targeted level. Postimplantation axial scans with sagittal and coronal reformations

are obtained. The CT scanning technique for screw placement has a low radiation dose equivalent to that of a chest radiograph's radiation (1 mSv). The patient is observed in the recovery area for 1 hour and discharged.

**Case Example.** In an outpatient setting, a patient with a tumor located at a midthoracic portion (between T-7 and T-8 [Fig. 2A]) of the spine underwent preoperative placement of the fiducial marker screw under CT guidance (Fig. 2B and C). A postimplantation CT scout image or a sagittally reconstructed CT scan was used to count the exact level of screw placement up from the sacrum (Fig. 2D). A tubular retractor was subsequently used for the minimally invasive removal of the spinal tumor.

### *Traditional Localization Method*

The traditional method of marking the thoracic vertebrae involved placing percutaneous sterile needles near the spinous process in a sequential fashion at every 3 levels starting at the sacrum. Fluoroscopy was then used to count the needles and the vertebral levels from the sacrum to the target level (Fig. 3A). This method was time consuming the further the target level was away from the sacrum (compare Fig. 3A with Fig. 3B for localization with a minimally invasive technique).

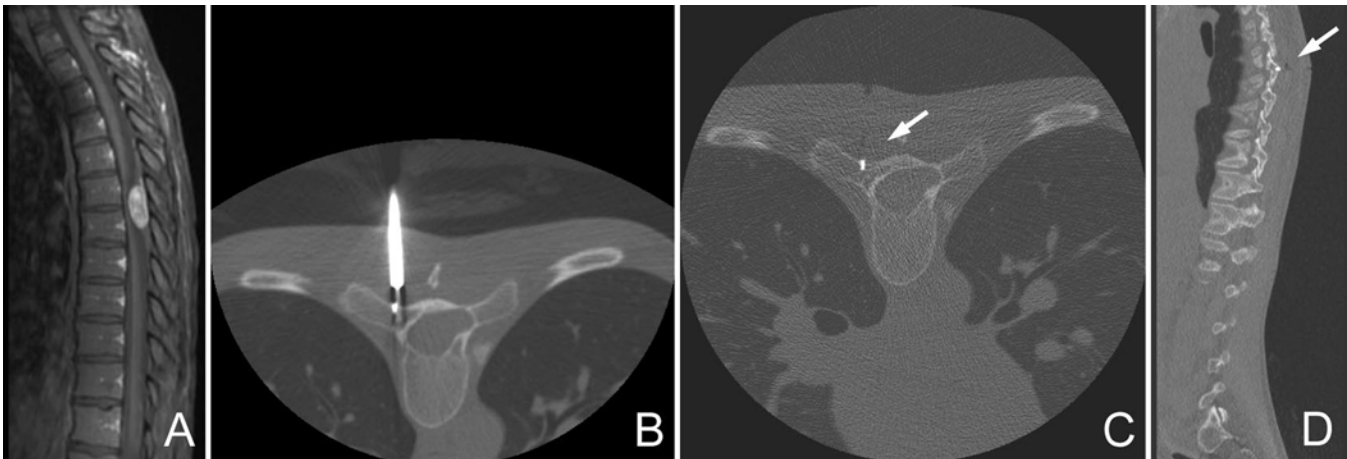
## Results

Data obtained in 26 patients who underwent fiducial screw placement were compared with a historical cohort of 26 patients who underwent the traditional method of localization. Table 1 summarizes the general characteristics of the groups in terms of demographics, indications for surgery, levels of surgery, and surgical approach.

No complications related to fiducial screw placement occurred in the 26 patients who underwent preoperative thoracic spine fiducial screw placement. In addition, there was no incidence of wrong-level surgery. In comparison, the historical cohort of 26 patients also had no wrong-level surgeries. However, in the experience of the senior author (P.V.M.), the fluoroscopy localization time was reduced dramatically (mean localization time 3 minutes vs 15 minutes, respectively) when the fiducial screw localization technique was used.

## Discussion

Avoidance of wrong-level surgery in the thoracic spine is important for patient safety.<sup>8</sup> Anatomical landmarks such as the prominent C-7 spinous process are often not reliable. Furthermore, patients have anatomical variations in the number of thoracic rib-bearing vertebrae that can mislead one during radiographic localization. Traditional intraoperative localization of the thoracic spine involves either fluoroscopy or long-cassette radiographs and counting of the vertebrae beginning from the craniocervical or the lumbosacral junctions. Obtaining fluoroscopic or long-cassette radiographs of adequate quality can be especially difficult in obese patients or in patients with decreased bone density. Furthermore, the presence of transitional vertebrae of the lumbosacral spine has been reported to range from 13.2% to 30% in MR imaging series.<sup>2,11,15</sup>



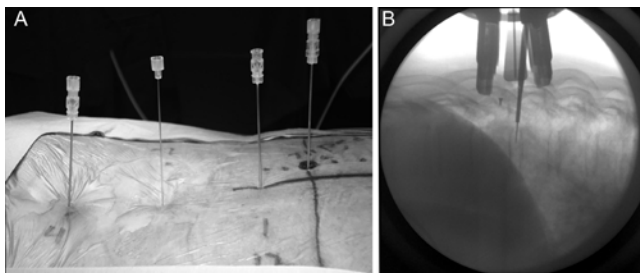
**FIG. 2.** **A:** Spinal tumor seen on a T1-weighted postcontrast sagittal MR image obtained in the thoracic region. **B:** Computed tomography–guided placement of the fiducial. **C:** Fiducial (arrow) placed in the thoracic vertebra of interest. Bony scalloping is seen on the side adjacent to the fiducial marker. **D:** Sagittal CT scan showing the fiducial marker (arrow).

The reported incidence of wrong-level surgery in the thoracic spine is relatively low. However, this problem may be underreported. Efforts to identify the correct side and level of surgery preoperatively by marking the patient and performing a time-out procedure may reduce errors.<sup>12</sup>

The ideal intraoperative technique for thoracic level localization should be simple, quick, reproducible, and accurate during the procedure. We found that the use of intraoperative fluoroscopy alone as a localizing tool increases operating room time and exposes operating room personnel to radiation. Furthermore, the T1–5 area can be difficult to visualize, and the surgeon may not be confident of the operative level.

In the past, skin surface markers were tried as localizing tools. Preoperative skin surface localization with halibut liver oil<sup>19</sup> and longitudinal grid tube surface markers filled with radiopaque material<sup>4</sup> were introduced in 1988.<sup>19</sup> Rosahl et al.<sup>18</sup> used adhesive, disposable skin markers filled with radiopaque material that can be visualized on MR imaging and CT scanning to localize intradural lesions of the thoracic spine. This was a simple method but is problematic in patients with scoliosis, spinal deformity, obesity, and heavy skin folding. The skin markers may also shift during positioning.

Hsu et al.<sup>8</sup> described a technique of using polymethylmethacrylate cement injected into the vertebral bodies to identify the level. However, the risk of cement leakage causing neural compression has been reported to be as



**FIG. 3.** **A:** Multiple needles inserted as flag posts from the lumbosacral region to identify the level of interest. **B:** Minimally invasive thoracic discectomy, with fiducial seen on the vertebra.

high as 13.6%.<sup>10</sup> The authors recommended this procedure only when standard methods are not possible to localize the lesion.

Image guidance has also been described as a localization method.<sup>19</sup> This requires placement of a reference frame, which cannot change in relation to the spine once the patient is registered. Furthermore, the changes in spinal alignment with intraoperative positioning may cause errors in registration.<sup>14</sup> Additionally, the reference frame may become dislodged, and lesions more than 3 levels away from the reference frame may not be accurately localized.

Intraoperative transligamentous ultrasound has been reported to identify the correct level of spinal pathology, but it can be limited by a narrow interlaminar window, calcified ligamentum flavum, and operator skill.<sup>7</sup> These various techniques are summarized in Table 2.

The technique that we have described has several advantages over the others. Preoperative localization is per-

**TABLE 1: Summary of demographic and surgical data\***

Factor	No. of Patients (%)		p Value
	Fiducial Placement	Fluoroscopy/ Radiograph Alone	
no. of patients	26	26	
male sex	11 (42)	17 (65)	0.103
mean age†	58 ± 15	59 ± 13	0.8
thoracic levels			0.628
T1–4	5 (20)	3 (12)	
T5–8	11 (42)	9 (35)	
T9–12	10 (38)	14 (54)	
pathology			0.681
tumors	12	9	
HNP	6	13	
others	8	4	

\* HNP = herniated nucleus pulposus; others = arachnoid cyst, ossified ligamentum flavum, osteomyelitis.

† Value represents the mean ± SD.

## Percutaneous fiducial screw placement for localization

**TABLE 2: Advantages and disadvantages of the fiducial screw localization in the thoracic spine**

advantages
1) fiducial marker screw can be placed on an outpatient basis at any time prior to op
2) fiducial marker screw & pathology can be reconfirmed w/ preop CT or MRI
3) reformatted CT or MR images of whole spine can be referenced intraoperatively to verify surgical level
4) easily identified on intraop fluoroscopy
5) may be removed intraoperatively after level of pathology is confirmed
disadvantages
1) cost (including screw & preop image studies)
2) need for limited low-radiation dose preop CT scan
3) potential risk of infection
4) potential risk of screw malpositioning
5) mild MRI artifact from fiducial screw

formed in an outpatient setting with the level of pathology confirmed on CT scan. The fiducial screws are readily identifiable on intraoperative fluoroscopy and may be left in place or removed during the thoracic procedure (Table 3). With our technique, the time spent on intraoperative localization is much shorter than with fluoroscopy alone, and the surgeon's confidence in the correct identification of the operative level is greater.

The average radiation exposure (effective dose) for placement of a fiducial screw under low-dose CT guidance

(which is how we do this) is 1 mSv. For reference, the average radiation exposure for a spine radiograph is 1.5 mSv.<sup>17</sup> Using our technique, we expose the patient to less radiation because the procedure required 12 minutes less fluoroscopy time intraoperatively. This reduction in fluoroscopic imaging compensates for the preoperative CT radiation dose.

We estimate that the placement of a fiducial marker under CT guidance costs around \$600 US including the cost of the screw. One fiducial screw costs about \$70 US.<sup>16</sup> It should be noted that 12 minutes of operating room time, at \$60–\$90 per minute,<sup>3,6</sup> costs \$700–\$1000. Therefore, the fiducial screw placement is relatively cost neutral. This fiducial screw localization technique is not necessary for all patients. We typically use it for patients with thoracic spine pathology with abnormal bony landmarks (13 ribs, transitional lumbar vertebrae) or in obese patients.

### Conclusions

The use of preoperative percutaneous fiducial screws for intraoperative localization of the target level in the thoracic spine is safe, efficient, and accurate for identifying the correct surgical level. Our method is a good alternative to the conventional methods of localization with fluoroscopy or radiography alone. The fiducial marker screws can be placed using CT guidance on an outpatient basis, and there is a reduction in the amount of intraoperative fluoroscopy time needed to localize the lesion. The fiducial screw placement appears to be cost neutral. When a low-dose CT protocol is used, the fiducial screw placement technique is not associated with higher exposure of the patient to radiation compared with a standard fluoroscopic localization

**TABLE 3: Comparison of various techniques for localization\***

Techniques	Advantages	Disadvantages
radiographic skin markers	easy & inexpensive noninvasive	inaccurate in patients w/ scoliosis, obesity, & heavy skin folding  potential shifting or dislodgment of markers w/ patient positioning
computer-assisted surgery (navigation)	accurate simultaneous identification of surrounding structures no radiation exposure for operating personnel	expensive & not readily available reference point for navigation must be maintained problems w/ obtaining reliable registration unreliable when target level is >3 levels away from reference frame setup time
VB PMMA injection	high accuracy no radiation exposure for operating personnel	op-related morbidity including cement leakage risk of adjacent-level VB fracture
methylene blue dye marking on spinous process	minimally invasive no radiation exposure for operating personnel	diffusion of dye toward adjacent spinous processes  needs to be performed just prior to op not feasible for anterior techniques risk of infection
intraop transligamentous ultrasound localization	noninvasive no radiation exposure for operating personnel or patient	not possible when interlaminar space is small limitation in ligamentum flavum calcification operator dependent

\* PMMA = polymethylmethacrylate; VB = vertebral body.



technique. This fiducial screw marker technique is most useful in patients with abnormal bony anatomy (13 rib-bearing vertebrae or 6 lumbar vertebrae) and in patients with a large body mass index that inhibits intraoperative radiographic visualization to count the thoracic level of interest.

#### Disclosure

Dr. Mummaneni is a past consultant for DePuy Spine and Medtronic. He receives a royalty from DePuy Spine (not related to this manuscript) and from Quality Medical Publishing.

Author contributions to the study and manuscript preparation include the following. Conception and design: Wu, Upadhyaya, Chin, Mummaneni. Acquisition of data: Wu, Upadhyaya, Chin, Mummaneni. Analysis and interpretation of data: Wu, Upadhyaya, Mummaneni. Drafting the article: Wu, Upadhyaya, Chin, Balamurali. Critically revising the article: Wu, Upadhyaya, Mummaneni. Approved the final version of the paper on behalf of all authors: Wu. Statistical analysis: Upadhyaya. Administrative/technical/material support: Chin, Mummaneni. Study supervision: Mummaneni.

#### References

- Bolger C, Wigfield C: Image-guided surgery: applications to the cervical and thoracic spine and a review of the first 120 procedures. **J Neurosurg** **92** (2 Suppl):175–180, 2000
- Chang HS, Nakagawa H: Altered function of lumbar nerve roots in patients with transitional lumbosacral vertebrae. **Spine (Phila Pa 1976)** **29**:1632–1635, 2004
- Chatterjee A, McCarthy JE, Montagne SA, Leong K, Kerrigan CL: A cost, profit, and efficiency analysis of performing carpal tunnel surgery in the operating room versus the clinic setting in the United States. **Ann Plast Surg** **66**:245–248, 2011
- English PT, Dougal C, Griffiths PD, Gholkar A: Technical note: a simple method for skin/lesion localization using magnetic resonance imaging. **Br J Radiol** **67**:813–815, 1994
- Goodkin R, Laska LL: Wrong disc space level surgery: medicolegal implications. **Surg Neurol** **61**:323–342, 2004
- Hecht AC, Koehler SM, Laudone JC, Jenkins A, Qureshi S: Is intraoperative CT of posterior cervical spine instrumentation cost-effective and does it reduce complications? **Clin Orthop Relat Res** **469**:1035–1041, 2011
- Henegar MM, Vollmer DG, Silbergeld DL: Intraoperative transligamentous ultrasound in the evaluation of thoracic intraspinal disease. Technique. **Spine (Phila Pa 1976)** **21**:124–127, 1996
- Hsu W, Sciubba DM, Sasson AD, Khavkin Y, Wolinsky JP, Gailloud P, et al: Intraoperative localization of thoracic spine level with preoperative percutaneous placement of intravertebral polymethylmethacrylate. **J Spinal Disord Tech** **21**:72–75, 2008
- Kalfas IH: Image-guided spinal navigation. **Clin Neurosurg** **46**:70–88, 2000
- Lin EP, Ekholm S, Hiwatashi A, Westesson PL: Vertebroplasty: cement leakage into the disc increases the risk of new fracture of adjacent vertebral body. **AJNR Am J Neuroradiol** **25**:175–180, 2004
- Luoma K, Vehmas T, Raininko R, Luukkonen R, Riihimäki H: Lumbosacral transitional vertebra: relation to disc degeneration and low back pain. **Spine (Phila Pa 1976)** **29**:200–205, 2004
- Mody MG, Nourbakhsh A, Stahl DL, Gibbs M, Alfawareh M, Garges KJ: The prevalence of wrong level surgery among spine surgeons. **Spine (Phila Pa 1976)** **33**:194–198, 2008
- Nowitzke A, Wood M, Cooney K: Improving accuracy and reducing errors in spinal surgery—a new technique for thoracolumbar-level localization using computer-assisted image guidance. **Spine J** **8**:597–604, 2008
- Paolini S, Ciappetta P, Missori P, Raco A, Delfini R: Spinous process marking: a reliable method for preoperative surface localization of intradural lesions of the high thoracic spine. **Br J Neurosurg** **19**:74–76, 2005
- Peh WC, Siu TH, Chan JH: Determining the lumbar vertebral segments on magnetic resonance imaging. **Spine (Phila Pa 1976)** **24**:1852–1855, 1999
- Pop D, Venissac N, Bondiau PY, Mouroux J: Peroperative fiducial placement for postoperative stereotactic Cyberknife radiosurgery. **Interact Cardiovasc Thorac Surg** **10**:1034–1036, 2010
- Radiological Society North America: **Radiation Exposure in X-ray and CT Examinations**. ([http://www.radiologyinfo.org/en/safety/index.cfm?pg=sfty\\_xray](http://www.radiologyinfo.org/en/safety/index.cfm?pg=sfty_xray)) [Accessed October 7, 2011]
- Rosahl SK, Gharabaghi A, Liebig T, Feste CD, Tatagiba M, Samii M: Skin markers for surgical planning for intradural lesions of the thoracic spine. Technical note. **Surg Neurol** **58**:346–348, 2002
- Thomson JL: A simple skin marker for magnetic resonance imaging. **Br J Radiol** **61**:638–639, 1988

Manuscript submitted June 13, 2010.

Accepted March 23, 2011.

Please include this information when citing this paper: published online November 4, 2011; DOI: 10.3171/2011.3.SPINE10445.

Address correspondence to: Jau-Ching Wu, M.D., Department of Neurosurgery, Neurological Institute, Taipei Veterans General Hospital, Room 509, 17F, No. 201, Shih-Pai Road, Sec. 2, Beitou, Taipei 11217, Taiwan. email: jauching@gmail.com.