

Stereotactic Radiosurgery of Intracranial Chordomas, Chondrosarcomas, and Glomus Tumors

Hideyuki Kano, MD, PhD*, L. Dade Lunsford, MD

KEYWORDS

- Chordoma • Chondrosarcoma • Glomus tumor • Skull base • Stereotactic radiosurgery
- Gamma knife

KEY POINTS

- Chordomas and chondrosarcomas are rare, slow-growing, locally aggressive tumors with high recurrence rates that may prove disabling or fatal.
- Patients with intracranial chordomas and chondrosarcomas often require multimodality treatment, including surgical resection, fractionated radiation therapy, and stereotactic radiosurgery (SRS).
- SRS is an important management option for patients with recurrent or residual chordomas and chondrosarcomas that failed to respond to initial surgical resection and adjuvant radiation therapy.
- The local tumor control rate and prognosis is generally better for patients with chondrosarcomas than for those with chordomas.
- SRS can be used as an up-front treatment or as an adjuvant treatment for patients with recurrent or residual glomus jugulare tumors after surgical resection.

INTRODUCTION

Chordomas are slowly-growing, locally aggressive tumors that arise from embryonic remnants of the notochord and show a dural epithelial-mesenchymal differentiation.¹ They arise from the sacrococcygeal region in 50% to 60% of patients, from the skull base region in 25% to 35%, and from the vertebrae in 15%.² The natural history of untreated clival chordomas is dismal, with a mean survival of less than 1 year.³ Neurologic deficits tend to vary based on the location of the tumor. An abducens nerve deficit causing diplopia is the most frequent presenting sign.^{4,5}

CHORDOMAS

Therapeutic Options

Aggressive initial management, beginning with radical resection when possible and followed by fractionated radiation therapy or radiosurgery, improves overall outcome.⁶ Earlier recognition of these tumors^{7–10} facilitates aggressive therapy. Complete resection without significant morbidity is rarely feasible because these tumors tend to encase critical vessels and cranial nerves, or adhere to the brainstem.^{11–15} The recurrence rate, even after virtually complete resection, remains high.^{16,17} Recurrent tumors are even more challenging for

Disclosures: Dr Lunsford is a consultant for and a stockholder of AB Elekta.

Department of Neurological Surgery, The Center for Image-Guided Neurosurgery, UPMC Presbyterian, University of Pittsburgh School of Medicine, University of Pittsburgh, Suite B-400, 200 Lothrop Street, Pittsburgh, PA 15213, USA

* Corresponding author.

E-mail address: kanoh@upmc.edu

Neurosurg Clin N Am 24 (2013) 553–560

<http://dx.doi.org/10.1016/j.nec.2013.05.009>

1042-3680/13/\$ – see front matter © 2013 Elsevier Inc. All rights reserved.

extirpation. Most patients undergo adjuvant radiation therapy to reduce the risk of tumor recurrence. Chordomas are considered radioresistant tumors that require total fractionated radiation therapy doses in excess of 60 Gy to reduce recurrence rates.¹ Fractionated stereotactic radiation therapy using high-energy photons or fractionated charged particle radiation (most often protons) are the 2 most commonly administered forms of radiation for chordomas.^{18–22} Prior reports comparing results of photon irradiation with proton beam therapy rarely take into account the more recent evolution of photon-based treatments in which energies are higher, and targeting and delivery methods have been enhanced. Regardless of the radiation modality, the maximum dose of radiation that can be safely delivered is limited by the tolerance of the surrounding critical cranial nerve, brainstem, or temporal lobe structures.^{23–26}

Based on the principle of Bragg peak deposition of energy that reduces exit dose, fractionated, charged-particle radiation delivered by protons or carbon ions is thought by some to deliver a more radiobiologically potent dose to the tumor. The Bragg peak effect results in a rapid energy deposition at the target volume, with a steep dose drop-off beyond the target volume treated.²⁷ With proton beam radiation therapy, doses greater than 70 cobalt gray equivalent (CGE) are prescribed. CGE is an empiric measure of estimated radiation effect obtained through multiplying the conventional photon radiation dose in Gy by 1.2, a value that has been postulated but unproven to be the potential radiobiological advantage of proton Bragg peak radiation therapy. Published data indicate that experienced centers may achieve local tumor control rates of 67% to 88% at 3 years, 46% to 73% at 5 years, and 54% at 10 years. The overall survival rates are 67% to 81% at 5 years and 54% at 10 years.²⁸ These results are often interpreted as superior to those reported for chordomas treated by older fractionated photon radiation therapy techniques before the era of intensity-modulated radiation therapy (IMRT).²⁷ Using carbon ion therapy, Castro and colleagues²⁹ treated 53 patients with doses of 60 to 80 CGE. They reported 5-year local tumor control and overall survival rates of 63% and 75%, respectively. Schulz-Ertner and colleagues³⁰ reported that 96 patients with chordoma who underwent carbon ion fractionated radiation therapy showed 5-year local tumor control and overall survival rates of 70% and 88.5%, respectively. Late toxicity consisted of optic nerve neuropathy Radiation Therapy Oncology Group (RTOG)/European Organisation for Research and Treatment of Cancer (EORTC) grade 3 in 4.1% of the patients. Minor temporal lobe injury (RTOG/

EORTC grade 1–2) occurred in 7.2% of the patients.

Noel and colleagues³¹ reported the results of combined fractionated photon and proton radiation therapy in 90 patients with either chordomas ($n = 64$) or chondrosarcomas ($n = 26$) of the skull base. The tumors were treated to a median total dose of 67 CGE (range, 22–70 CGE). Photons represented two-thirds of the total delivered dose, and protons represented one-third. At a median follow-up of 34 months, local tumor control was achieved in 65 patients (72%). All 90 patients developed immediate adverse radiation effects, usually mild. However, 6% reported late grade III or IV radiation toxicities, including cranial nerve deficits and visual loss. Proton fractionated radiation therapy remains a relatively expensive strategy that is available in a limited but increasing number of facilities in the United States and abroad.

Clinical Outcomes of Stereotactic Radiosurgery

Stereotactic radiosurgery (SRS) is a surgical technique designed to achieve a greater radiobiological effect than conventional 3-dimensional conformal radiation therapy or IMRT. SRS has been used as a minimally invasive primary or adjuvant management option for chordomas (**Fig. 1, Table 1**).^{32–34} SRS using the Leksell Gamma Knife (Elekta Inc, Norcross, GA) is a surgical procedure that delivers cross-fired photon radiation generated from the decay of cobalt 60 sources in a single wheels-in-to-wheels-out procedure. Using linear accelerator technologies, such as the Accuray CyberKnife (Accuray, Sunnyvale, CA), SRS may be delivered in up to 5 treatment sessions. Delivery of such highly focused radiation in 1 to 5 sessions significantly increases the radiobiological effect of SRS compared with conventional fractionated radiation therapy. Using methods to evaluate radiobiological effects, the center of the tumor may receive a radiobiological effect 4 times of what can be safely delivered using conventional fractionated radiation or IMRT. SRS seems especially valuable for the treatment of relatively small residual or recurrent chordomas after prior surgical resection. SRS has been frequently added as a radiobiological boost to conventional fractionated radiation therapy. Krishnan and colleagues³³ treated 25 patients with cranial base chordoma with SRS using a median tumor margin dose of 15 Gy. The 5-year treated tumor control rate was 52% at a median follow-up of 4.5 years. Hasegawa and colleagues³² performed SRS on 27 patients with chordoma with median tumor

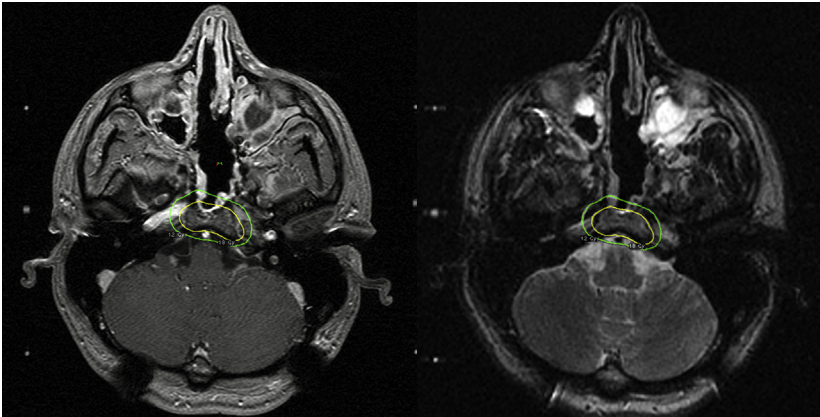


Fig. 1. T1-weighted contrast-enhanced (left) and T2-weighted (right) axial magnetic resonance imaging scan of residual chordoma involving clivus, showing the stereotactic radiosurgery target with a margin dose of 18 Gy.

margin doses of 14 Gy. They noted 5-year local tumor control and overall survival rates of 42% and 80%, respectively, at a median follow-up of 59 months. In their series, only tumor volumes of less than 20 cm³ were significantly associated with a longer progression-free survival (PFS). Liu and colleagues³⁵ reported on 28 patients with residual skull base chordoma who underwent SRS with median margin dose of 12.7 Gy. The average follow-up was 28 months and the mean tumor volume was 11.4 ± 7.4 cm³. The 5-year overall survival and in-field tumor control rates were 75.8% and 21.4%, respectively. No serious adverse radiation effects (AREs) were reported.

Kano and colleagues³⁶ reported that 6 participating centers of the North American Gamma Knife Consortium identified 71 patients who underwent Gamma Knife SRS for chordomas. The median patient age was 45 years (range, 7–80 years). The median SRS target volume was 7.1 cm³ (range, 0.9–109.0 cm³) and the median tumor margin dose was 15.0 Gy (range, 9–25 Gy). At a median

follow-up of 5 years after SRS (range, 0.6–14.0 years), 23 patients died because of tumor progression. The 5-year actuarial overall survival after SRS for the entire group was 80%. Tumor control was higher (93%) in patients who had not undergone prior fractionated radiation therapy (*n* = 50). Tumor control was reduced to 43% in patients who underwent prior fractionated radiation therapy (*n* = 21). Factors associated with longer patient survival included younger age, longer interval between initial diagnosis and SRS, no prior radiation therapy, fewer than 2 cranial nerve deficits, and smaller total tumor volumes. The 5-year treated tumor control rates after SRS for the entire group was 66% (69% for the no prior fractionated radiation therapy group and 62% for the prior fractionated radiation therapy group). Significant factors associated with reduced tumor control included older age, recurrent tumors, prior fractionated radiation therapy, and larger tumor volumes. Of 57 patients with pretreatment neurologic deficits, 17 (30%) experienced neurologic improvement. Of 65

Reference	N	Radiation	Median Margin Dose (range)	Tumor Volume	% Local Control	% Survival	Median Follow-up (mo)
Krishnan et al, ³³ 2005	19	SRS ± RT	15.0 Gy (10.0–20.0 Gy) ± 50.4 Gy (45.0–54.0 Gy)	14.4 cm ³	4 y: 55	NA	58
Hasegawa et al, ³² 2007	27	SRS	14 Gy (9–20 Gy)	19.7 cm ³	5 y: 72 10 y: 72	5 y: 84 10 y: 67	59
Liu et al, ³⁵ 2008	31	SRS	12.7 Gy (10.0–16.0 Gy)	11.4 cm ³	3 y: 64 5 y: 21	3 y: 91 5 y: 76	28
Kano et al, ³⁶ 2011	71	SRS ± RT	15 Gy (9–25 Gy)	7.1 cm ³	3 y: 79 5 y: 66	5 y: 80 7 y: 69	60

Abbreviations: NA, not available; RT, fractionated radiation therapy.

patients with clinical follow-up, 31 (48%) remained stable, but 17 (26%) eventually had deterioration in neurologic function. Deterioration was related to treated tumor progression in 8 patients, adjacent tumor progression in 3, treatment-associated AREs in 4, and both treated tumor progression and AREs in 2.

Summary

Maximal safe resection should be the primary initial treatment for chordomas. After recovery from surgery, fractionated Bragg peak proton radiation therapy at an experienced center remains an option for the additional treatment of chordomas. Careful planning and reduction of dose delivered to adjacent critical structures are critical components, whether using particle beam or modern fractionated photon radiation techniques. Long-term evaluation of neurocognitive effects are warranted because of the relatively higher dose that may be delivered via the entrance pathway within the temporal lobes. SRS after surgical resection also provides a reasonable benefit-to-risk profile for small- to medium-sized chordomas. SRS is an important option for patients with recurrent tumors that failed to respond to initial surgical resection. Current data suggest that it might well supplant radiation therapy as the next best option for residual smaller-volume tumors.

CHONDROSARCOMA

Chondrosarcomas are relatively slow-growing, locally invasive tumors that usually do not metastasize until very late in the natural history.¹² Cranial chondrosarcomas originate from primitive mesenchymal cells within the cartilaginous matrix of the skull base.² The imaging features and clinical presentations of patients harboring either chordomas or chondrosarcomas are similar. Chordomas have a tendency to cause brainstem compression because they arise from the clivus, whereas chondrosarcomas tend to affect the lower cranial nerves because they frequently originate from the occipitotemporal bone synchondrosis.³⁷ The most common presenting symptom of chondrosarcoma is diplopia, secondary to an abducens nerve palsy.³⁸ Using imaging alone to distinguish chondrosarcomas from chordomas is often difficult but important, because the prognosis is generally considered better for chondrosarcomas.^{28,39}

Therapeutic Options

Chondrosarcomas are rarely completely resectable, and additional management options must

be considered for residual tumors.^{40,41} Gay and colleagues¹² reported a 90% overall survival at 5 years for 14 patients who underwent either skull base surgery or surgery followed by radiation therapy. Crockard and colleagues⁴² reported a 93% 5-year survival rate for 17 patients who underwent surgery alone. Bloch and colleagues⁴³ found a recurrence rate of 44% in patients who underwent surgical resection alone, compared with 9% in patients who had surgery followed by radiation therapy. A recent review of the literature described 560 patients with intracranial chondrosarcomas, which were associated with a 5-year mortality rate of 11.5% and a median survival of 24 months. No association was seen between the rate of recurrence and the histologic grade of the tumor.⁴³ In a study of 8 patients with chondrosarcomas and 8 with chordomas of the skull base who underwent proton radiation therapy, Fuji and colleagues⁴⁴ reported a local control rate at 3 years of 86% and a median follow-up of 42 months. Other studies using proton radiation therapy have also reported overall survival and local tumor control rates at 5 years to be greater than 90%.⁴⁵⁻⁴⁷

Clinical Outcomes of SRS

Relatively few data exist to define the use of SRS in the multimodal management of chondrosarcoma (Fig. 2, Table 2). SRS has been shown to result in less toxicity to surrounding structures and have fewer complications than fractionated radiation therapy in the management of chondrosarcomas. Koga and colleagues⁴⁸ reported the results of 4 patients who had surgical resection followed by SRS at a median follow-up of 99 months. Three of the patients, who received margin doses of 15, 16, and 20 Gy, had no change in tumor size during follow-up. One patient who received a lower tumor margin dose of 12 Gy developed tumor recurrence 100 months after SRS. Hasegawa and colleagues³² studied 30 patients with chordomas and 7 patients with chondrosarcomas who underwent SRS. The 5-year PFS rate in patients with low-grade chondrosarcomas was 76%. A tumor volume of less than 20 mL significantly improved PFS. Krishnan and colleagues³³ reported that 4 patients with chondrosarcomas who underwent SRS had tumor control at 5 years.

Iyer and colleagues⁴⁹ studied 22 patients who underwent Gamma Knife SRS for residual or recurrent intracranial chondrosarcomas. Overall patient survival rates after SRS were 95%, 70%, and 56% at 1, 5, and 10 years, respectively. Factors associated with longer survival after SRS included a shorter interval (<6 months) between

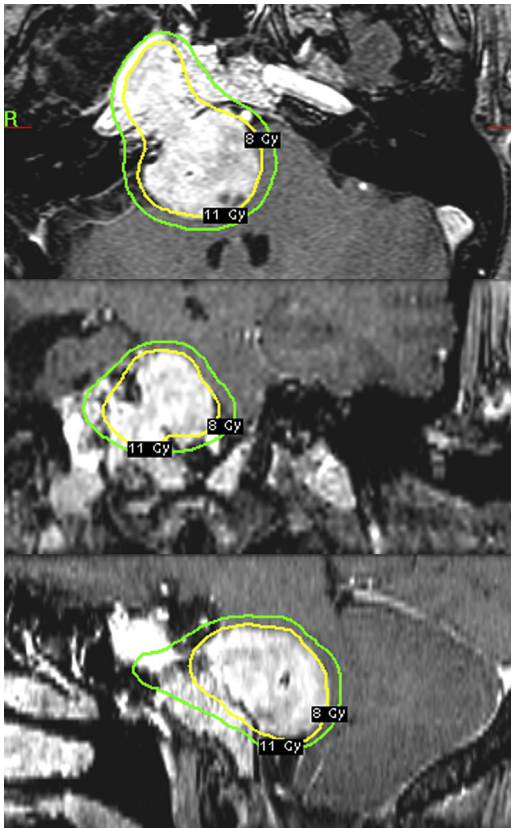


Fig. 2. T1-weighted contrast-enhanced axial (upper), coronal (middle), and sagittal (lower) magnetic resonance imaging scan of residual chondrosarcoma involving the right petroclival and cerebellopontine angle, showing the stereotactic radiosurgery target with a margin dose of 11 Gy.

diagnosis and SRS, age older than 40 years, and either a single or no prior resection. Treated tumor control rates were 91% at 1 year, 72% at 5 years, and 54% at 10 years. Factors associated with

longer PFS after SRS included patient age older than 40 years and no prior radiation therapy.

Summary

The ability to achieve tumor growth control of chondrosarcomas is likely to be enhanced by earlier recognition and the application of multimodal treatment in appropriate patients. Maximal safe resection should be the primary initial management of chondrosarcomas. Gamma Knife radiosurgery is a reasonable therapeutic option as an adjuvant treatment after resection in selected patients with chondrosarcomas.

GLOMUS JUGULARE TUMORS

Glomus jugulare tumors are rare, highly vascularized tumors that arise from the paraganglionic structures of the glossopharyngeal and vagal nerves. Because of their highly vascular nature and generally inaccessible anatomic location, surgical resection is often challenging. The ideal treatment for patients with a glomus tumor remains controversial. Treatment options include surgical resection, endovascular embolization, fractionated radiation therapy, and SRS alone or in combination.

Clinical Outcomes of SRS

Liscak and colleagues⁵⁰ reported on 52 patients with glomus jugulare tumors treated with SRS (Fig. 3, Table 3); 24 had prior surgical resection, 14 had prior embolization, and 5 had prior RT. The median tumor volume was 5.7 cm³ (range, 0.5–27.0 cm³) and median margin dose was 16.5 Gy (range, 10–30 Gy). All patients had tumor control at a median of 24 months. The neurologic symptom control rate was 96%. Ivan and

Reference	N	Radiation	Median Margin Dose	Tumor Volume	% Local Control	% Survival	Median Follow-up (mo)
Krishnan et al, ³³ 2005	4	SRS	15 Gy	14.4 cm ³	5 y: 100	NA	58
Hasegawa et al, ³² 2007	7	SRS	14 Gy	19.7 cm ³	5 y: 76 10 y: 67	5 y: 90 10 y: 53	59
Cho et al, ⁵⁴ 2008	11	SRS ± RT	12.7 Gy ± 58.2 Gy	3.7 cm ³	5 y: 89 10 y: 80	5 y: 100 10 y: 100	56
Koga et al, ⁴⁸ 2010	4	SRS	15.6 Gy	NA	5 y: 100	NA	65
Iyer et al, ⁴⁹ 2012	22	SRS ± RT	15 Gy	8.0 cm ³	5 y: 72 10 y: 54	5 y: 70 10 y: 56	60

Abbreviations: NA, not available; RT, fractionated radiation therapy.

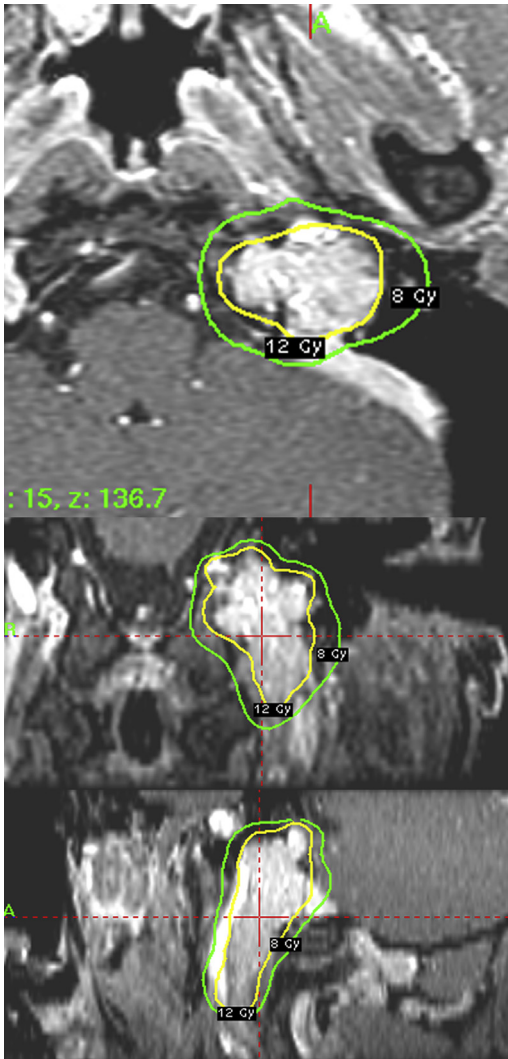


Fig. 3. T1-weighted contrast-enhanced axial (upper), coronal (middle), and sagittal (lower) magnetic resonance imaging scan of glomus jugulare tumor, showing the stereotactic radiosurgery target with a margin dose of 12 Gy.

colleagues⁵¹ reported a meta-analysis of tumor control and morbidity for patients with glomus jugulare tumors. They identified 869 patients with glomus jugulare tumors from 46 publications. Patients underwent gross total resection alone had a tumor control rate of 86% at a mean follow-up of 88 months. Patients who underwent subtotal resection followed by SRS had a tumor control rate of 71% at a mean follow-up of 96 months. Patients who underwent SRS alone had a tumor control rate of 95% at a mean follow-up of 71 months. Patients who underwent gross total resection sustained worse rates of cranial nerve (CN) deficits with regard to CN IX–XI than those who underwent SRS alone.

In a meta-analysis of 19 studies involving 335 patients with glomus jugulare tumors who underwent SRS, Guss and colleagues⁵² reported that 97% of patients experienced tumor control and 95% experienced clinical control. Sheehan and colleagues⁵³ performed a large retrospective multicenter study of Gamma Knife SRS for glomus jugular tumors, involving 134 procedures in 132 patients, with a median follow-up of 50.5 months. Prior resection was performed in 51 patients, and prior fractionated radiation therapy was performed in 6 patients. The median tumor volume was 5.5 cm³ (range, 0.6–58.6 cm³). The median margin dose was 15 Gy (10–18 Gy). The 5-year tumor control rate was 88% after SRS. Absence of trigeminal nerve dysfunction at the time of radiosurgery and higher number of isocenters were significantly associated with PFS. Patients showing new or progressive cranial nerve deficits were also likely to show tumor progression. Pulsatile tinnitus improved in 49% of patients who reported it at presentation. New or progressive cranial nerve deficits were noted in 15% of patients, and improvement in preexisting cranial nerve deficits was observed in 11% of patients. No patient died as a result of tumor progression.

Table 3

Studies and patient characteristics in published series of glomus jugulare tumor treated with SRS

Reference	N	Radiation	Median Margin Dose	Tumor Volume	% Local Control	% Symptom Control	Median Follow-up (mo)
Liscak et al, ⁵⁰ 1999	66	SRS ± RT	16.5 Gy	5.7 cm ³	100	96	24
Pollock et al, ⁵⁵ 2004	42	SRS	14.9 Gy	19.7 cm ³	97	NA	44
Gerosa et al, ⁵⁶ 2006	20	SRS	17.5 Gy	7 cm ³	100	90	50
Genc et al, ⁵⁷ 2010	18	SRS	15.6 Gy	5.5 cm ³	94	94	53
Sheehan et al, ⁵³ 2012	134	SRS ± RT	15 Gy	5.5 cm ³	92.7	85	50.5

Abbreviations: NA, not available; RT, fractionated radiation therapy.

Summary

SRS affords a high rate of local tumor control and a low risk of neurologic complications for patients with glomus jugulare tumors. SRS can be used as an up-front treatment or as an additional treatment for those with recurrent or residual tumor after surgical resection.

REFERENCES

- Chugh R, Tawbi H, Lucas DR, et al. Chordoma: the nonsarcoma primary bone tumor. *Oncologist* 2007;12(11):1344–50.
- Heffelfinger MJ, Dahlin DC, MacCarty CS, et al. Chordomas and cartilaginous tumors at the skull base. *Cancer* 1973;32(2):410–20.
- Eriksson B, Gunterberg B, Kindblom LG. Chordoma. A clinicopathologic and prognostic study of a Swedish national series. *Acta Orthop Scand* 1981;52(1):49–58.
- Nishigaya K, Kaneko M, Ohashi Y, et al. Intradural retroclival chordoma without bone involvement: no tumor regrowth 5 years after operation. Case report. *J Neurosurg* 1998;88(4):764–8.
- Weber AL, Liebsch NJ, Sanchez R, et al. Chordomas of the skull base. Radiologic and clinical evaluation. *Neuroimaging Clin N Am* 1994;4(3):515–27.
- Carpentier A, Polivka M, Blanquet A, et al. Suboccipital and cervical chordomas: the value of aggressive treatment at first presentation of the disease. *J Neurosurg* 2002;97(5):1070–7.
- Anegawa T, Rai M, Hara K, et al. An unusual cervical chordoma: CT and MRI. *Neuroradiology* 1996;38(5):466–7.
- Ducou le Pointe H, Brugieres P, Chevalier X, et al. Imaging of chordomas of the mobile spine. *J Neuroradiol* 1991;18(3):267–76.
- Murphy JM, Wallis F, Toland J, et al. CT and MRI appearances of a thoracic chordoma. *Eur Radiol* 1998;8(9):1677–9.
- Smolders D, Wang X, Drevelengas A, et al. Value of MRI in the diagnosis of non-clival, non-sacral chordoma. *Skeletal Radiol* 2003;32(6):343–50.
- al-Mefty O, Borba LA. Skull base chordomas: a management challenge. *J Neurosurg* 1997;86(2):182–9.
- Gay E, Sekhar LN, Rubinstein E, et al. Chordomas and chondrosarcomas of the cranial base: results and follow-up of 60 patients. *Neurosurgery* 1995;36(5):887–96 [discussion: 896–7].
- Maira G, Pallini R, Anile C, et al. Surgical treatment of clival chordomas: the transsphenoidal approach revisited. *J Neurosurg* 1996;85(5):784–92.
- Sen CN, Sekhar LN, Schramm VL, et al. Chordoma and chondrosarcoma of the cranial base: an 8-year experience. *Neurosurgery* 1989;25(6):931–40 [discussion: 940–1].
- Uttley D, Moore A, Archer DJ. Surgical management of midline skull-base tumors: a new approach. *J Neurosurg* 1989;71(5 Pt 1):705–10.
- Menezes AH, Gantz BJ, Traynelis VC, et al. Cranial base chordomas. *Clin Neurosurg* 1997;44:491–509.
- Tzortzidis F, Elahi F, Wright D, et al. Patient outcome at long-term follow-up after aggressive microsurgical resection of cranial base chordomas. *Neurosurgery* 2006;59(2):230–7 [discussion: 230–7].
- Igaki H, Tokuyue K, Okumura T, et al. Clinical results of proton beam therapy for skull base chordoma. *Int J Radiat Oncol Biol Phys* 2004;60(4):1120–6.
- Noel G, Feuvret L, Calugaru V, et al. Chordomas of the base of the skull and upper cervical spine. One hundred patients irradiated by a 3D conformal technique combining photon and proton beams. *Acta Oncol* 2005;44(7):700–8.
- Schulz-Ertner D, Nikoghosyan A, Thilmann C, et al. Results of carbon ion radiotherapy in 152 patients. *Int J Radiat Oncol Biol Phys* 2004;58(2):631–40.
- Terahara A, Niemierko A, Goitein M, et al. Analysis of the relationship between tumor dose inhomogeneity and local control in patients with skull base chordoma. *Int J Radiat Oncol Biol Phys* 1999;45(2):351–8.
- Weber DC, Rutz HP, Pedroni ES, et al. Results of spot-scanning proton radiation therapy for chordoma and chondrosarcoma of the skull base: the Paul Scherrer Institut experience. *Int J Radiat Oncol Biol Phys* 2005;63(2):401–9.
- Debus J, Hug EB, Liebsch NJ, et al. Brainstem tolerance to conformal radiotherapy of skull base tumors. *Int J Radiat Oncol Biol Phys* 1997;39(5):967–75.
- Habrand IL, Austin-Seymour M, Birnbaum S, et al. Neurovisual outcome following proton radiation therapy. *Int J Radiat Oncol Biol Phys* 1989;16(6):1601–6.
- Pai HH, Thornton A, Katznelson L, et al. Hypothalamic/pituitary function following high-dose conformal radiotherapy to the base of skull: demonstration of a dose-effect relationship using dose-volume histogram analysis. *Int J Radiat Oncol Biol Phys* 2001;49(4):1079–92.
- Slater JD, Austin-Seymour M, Munzenrider J, et al. Endocrine function following high dose proton therapy for tumors of the upper clivus. *Int J Radiat Oncol Biol Phys* 1988;15(3):607–11.
- Amichetti M, Cianchetti M, Amelio D, et al. Proton therapy in chordoma of the base of the skull: a systematic review. *Neurosurg Rev* 2009;32(4):403–16.
- Munzenrider JE, Liebsch NJ. Proton therapy for tumors of the skull base. *Strahlenther Onkol* 1999;175(Suppl 2):57–63.

29. Castro JR, Linstadt DE, Bahary JP, et al. Experience in charged particle irradiation of tumors of the skull base: 1977-1992. *Int J Radiat Oncol Biol Phys* 1994;29(4):647-55.
30. Schulz-Ertner D, Karger CP, Feuerhake A, et al. Effectiveness of carbon ion radiotherapy in the treatment of skull-base chordomas. *Int J Radiat Oncol Biol Phys* 2007;68(2):449-57.
31. Noel G, Feuvret L, Ferrand R, et al. Radiotherapeutic factors in the management of cervical-basal chordomas and chondrosarcomas. *Neurosurgery* 2004;55(6):1252-60 [discussion: 1260-2].
32. Hasegawa T, Ishii D, Kida Y, et al. Gamma knife surgery for skull base chordomas and chondrosarcomas. *J Neurosurg* 2007;107(4):752-7.
33. Krishnan S, Foote RL, Brown PD, et al. Radio-surgery for cranial base chordomas and chondrosarcomas. *Neurosurgery* 2005;56(4):777-84 [discussion: 777-84].
34. Martin JJ, Niranjana A, Kondziolka D, et al. Radio-surgery for chordomas and chondrosarcomas of the skull base. *J Neurosurg* 2007;107(4):758-64.
35. Liu AL, Wang ZC, Sun SB, et al. Gamma knife radiosurgery for residual skull base chordomas. *Neurol Res* 2008;30(6):557-61.
36. Kano H, Iqbal FO, Sheehan J, et al. Stereotactic radiosurgery for chordoma: a report from the North American gamma knife consortium. *Neurosurgery* 2011;68(2):379-89.
37. Volpe NJ, Liebsch NJ, Munzenrider JE, et al. Neuro-ophthalmologic findings in chordoma and chondrosarcoma of the skull base. *Am J Ophthalmol* 1993;115(1):97-104.
38. Bloch OG, Jian BJ, Yang I, et al. Cranial chondrosarcoma and recurrence. *Skull Base* 2010;20(3):149-56.
39. Goel A. Chordoma and chondrosarcoma: relationship to the internal carotid artery. *Acta Neurochir (Wien)* 1995;133(1-2):30-5.
40. Sekhar LN, Pranatariharan R, Chanda A, et al. Chordomas and chondrosarcomas of the skull base: results and complications of surgical management. *Neurosurg Focus* 2001;10(3):E2.
41. Sen CN, Sekhar LN. The subtemporal and preauricular infratemporal approach to intradural structures ventral to the brain stem. *J Neurosurg* 1990;73(3):345-54.
42. Crockard HA, Cheeseman A, Steel T, et al. A multidisciplinary team approach to skull base chondrosarcomas. *J Neurosurg* 2001;95(2):184-9.
43. Bloch OG, Jian BJ, Yang I, et al. A systematic review of intracranial chondrosarcoma and survival. *J Clin Neurosci* 2009;16(12):1547-51.
44. Fuji H, Nakasu Y, Ishida Y, et al. Feasibility of proton beam therapy for chordoma and chondrosarcoma of the skull base. *Skull Base* 2011;21(3):201-6.
45. Hug EB, Loredon LN, Slater JD, et al. Proton radiation therapy for chordomas and chondrosarcomas of the skull base. *J Neurosurg* 1999;91(3):432-9.
46. Kortjen AG, ter Berg HJ, Spincemaille GH, et al. Intracranial chondrosarcoma: review of the literature and report of 15 cases. *J Neurol Neurosurg Psychiatry* 1998;65(1):88-92.
47. Rosenberg AE, Nielsen GP, Keel SB, et al. Chondrosarcoma of the base of the skull: a clinicopathologic study of 200 cases with emphasis on its distinction from chordoma. *Am J Surg Pathol* 1999;23(11):1370-8.
48. Koga T, Shin M, Saito N. Treatment with high marginal dose is mandatory to achieve long-term control of skull base chordomas and chondrosarcomas by means of stereotactic radiosurgery. *J Neurooncol* 2010;98(2):233-8.
49. Iyer A, Kano H, Kondziolka D, et al. Stereotactic radiosurgery for intracranial chondrosarcoma. *J Neurooncol* 2012;108(3):535-42.
50. Liscak R, Vladyka V, Wowra B, et al. Gamma Knife radiosurgery of the glomus jugulare tumour—early multicentre experience. *Acta Neurochir (Wien)* 1999;141(11):1141-6.
51. Ivan ME, Sughrue ME, Clark AJ, et al. A meta-analysis of tumor control rates and treatment-related morbidity for patients with glomus jugulare tumors. *J Neurosurg* 2011;114(5):1299-305.
52. Guss ZD, Batra S, Limb CJ, et al. Radiosurgery of glomus jugulare tumors: a meta-analysis. *Int J Radiat Oncol Biol Phys* 2011;81(4):e497-502.
53. Sheehan JP, Tanaka S, Link MJ, et al. Gamma knife surgery for the management of glomus tumors: a multicenter study. *J Neurosurg* 2012;117(2):246-54.
54. Cho YH, Kim JH, Khang SK, et al. Chordomas and chondrosarcomas of the skull base: comparative analysis of clinical results in 30 patients. *Neurosurg Rev* 2008;31(1):35-43 [discussion].
55. Pollock BE. Stereotactic radiosurgery in patients with glomus jugulare tumors. *Neurosurg Focus* 2004;17(2):E10.
56. Gerosa M, Visca A, Rizzo P, et al. Glomus jugulare tumors: the option of gamma knife radiosurgery. *Neurosurgery* 2006;59(3):561-9 [discussion].
57. Genc A, Bicer A, Abacioglu U, et al. Gamma knife radiosurgery for the treatment of glomus jugulare tumors. *J Neurooncol* Mar 2010;97(1):101-8.